

Trunk and Genitalia



1

Chest Wall Reconstruction

Parag Sahasrabudhe, Vinay Kant Shankhdhar, and Vijay Langer

➤ **Introduction**

➤ **Anatomy and Physiology**

➤ **Etiology**

• **Postsurgical**

- ◇ Postoperative Median Sternotomy Wound
- ◇ Exposure of Pacemaker

• **Postoncological**

- ◇ Neoplasms
- ◇ Radiation Necrosis

• **Traumatic Chest Wall Defects**

• **Postburn Chest Wall Defects**

• **Infections**

- ◇ Empyema
- ◇ Osteomyelitis
- ◇ Bronchopleural Fistulas

➤ **Indications for Chest Wall Reconstruction**

• **Only Soft Tissue Reconstruction**

• **Bony and Soft Tissue Reconstruction**

➤ **Goals of Chest Wall Reconstruction**

➤ **Reconstruction of the Chest Wall**

• **Component Reconstruction**

- ◇ Skeletal Reconstruction
- ◇ Soft Tissue Reconstruction

➤ **Median Sternotomy Wound**

• **Classification**

• **Preoperative Evaluation and Patient Presentation**

• **Surgical Treatment Options**

- ◇ Debridement
- ◇ Definitive Closure—Flap Options and Negative Pressure Wound Therapy

➤ **Congenital Chest Wall Deformities**

• **Embryology**

• **Pectus Excavatum**

- ◇ Introduction
- ◇ Clinical Profile
- ◇ Clinical Presentation
- ◇ Treatment
- ◇ Postoperative Care
- ◇ Outcomes/Comparison
- ◇ Complications

• **Pectus Carinatum**

- ◇ Introduction
- ◇ Clinical Profile
- ◇ Treatment
- ◇ Outcome
- ◇ Complications

• **Poland Syndrome**

- ◇ Introduction
- ◇ Clinical Profile
- ◇ Treatment

• **Sternal Clefts**

Introduction

Complicated chest surgeries are a challenge not only for a reconstructive surgeon but also for anesthetists. The history of the development of chest surgeries thus goes hand in hand with the development of anesthesia with better airway control, improved surgical techniques, and a better understanding to manage the sequel of the surgeries.

Aimar (1778) was the first to perform chest wall resection, later in 1899 Parham resected sarcoma involving three ribs.¹

The advent of double-lumen tubes in anesthesia and positive pressure ventilation further made it possible to provide ventilation during pneumonectomies and chest wall resections. Tansini used latissimus dorsi myocutaneous flap for covering a defect after radical mastectomy.² Fascia lata was used by Watson and James in 1940s for closure of skeletal wound defects.³ Sternotomy wound closure by ribs was first done by Bisgard and Swenson (1948), however, Campbell in 1950 used latissimus dorsi transposition for coverage of anterior thoracic wall defect.⁴ Improvements in reconstructive and microsurgical techniques now enable us to cover huge defects using perforator, pedicle, or free flaps.

In 1957, the introduction of the median sternotomy to allow access to intrathoracic organs by Julian et al⁵ revolutionized the field of thoracic surgery as it became the incision of choice for most of the cardiac procedures. Since this benchmark introduction, sternal wound infection and dehiscence have been reported to occur in 0.2 to 10%⁶ cases and mortality rates range from 0.5 to 20%.⁶ The generally accepted incidence across the world is 1 to 2% (Culliford and colleagues 1976). Sternal wound infections are associated with high morbidity, mortality, prolonged hospital stay, and increased cost of hospitalization.⁷

Early treatment protocols were too conservative employing open packing of the debrided wound and required months to achieve a healed wound if the patient did not die of cardiac or graft rupture. Subsequent treatments were focused on the use of debridement and antibiotic irrigation through closed indwelling catheter systems.⁸ In 1976, Lee et al⁹ described the use of omentum to successfully close an open mediastinal defect. In 1980, Jurkiewicz et al¹⁰ introduced the concept of muscle and myocutaneous (pectoralis major and rectus abdominis) flaps for coverage of sternal wound defect. Sternal plate fixation methods were described but remained poorly accepted as implants did not go well with already infected bone tissue.¹¹ Currently, negative pressure wound therapy (NPWT) is accepted as one of the treatment modalities. It can be used to bridge the gap between debridement and definitive closure or as a first-line management for complicated sternal wounds.^{12,13}

Anatomy and Physiology

The chest wall (**Fig. 1.1**) houses important structures like heart and lungs. The design of the thoracic cavity is such

that it provides the forces and movements necessary for respiration. The bones constituting the thoracic cage are the sternum, ribs and costal cartilages, and clavicle and vertebral bodies. The muscles are the diaphragm, intercostals, and accessory muscles of respiration. The ribs are attached to the sternum and vertebrae. Any increase in the volume of the thoracic cage causes the lungs to expand (inspiration); similarly, any decrease causes the lungs to collapse (expiration). The intercostal muscles bring the ribs closer.

In inspiration, the accessory muscles of respiration are the sternocleidomastoids, scalene muscles, and external intercostals. During inspiration, the contraction of the diaphragm causes the central tendon to migrate inferiorly (increase in the vertical height of the thorax), the scalene muscles contract and fix the first rib, hence the contraction of the intercostals causes the central portion of the rib to move up and out (**Fig. 1.2**) (bucket handle movement), thus increasing the transverse diameter, and at the same time the sternum is raised up causing an increase in the anteroposterior diameter (**Fig. 1.3**) (pump handle movement), both result in an increase in volume of the thoracic cavity. The diaphragm also assists in respiration by contracting and pulling the lower ribs up toward the central tendon.

Expiration is largely a passive process. It is a result of the elastic recoil of the lungs and relaxation of the muscles; the quadratus lumborum muscle contraction can fix the 12th rib and then the contraction of the intercostals lower the rib cage; all of these reduce the volume and cause expiration.

Etiology

The etiology is listed below:

- Postsurgical
 - Poststernotomy wound.
 - Exposed pacemaker.
- Postoncological
 - Neoplasm.
 - Radiation necrosis.
- Traumatic chest wall defects.
- Postburn chest wall defects.
- Infections
 - Empyema.
 - Osteomyelitis.
 - Bronchopleural fistula.
- Congenital.

Postsurgical

Postoperative Median Sternotomy Wound

Most of the authors agree that risk factors include female gender, obesity, diabetes mellitus, use of bilateral mammary arteries, prolonged postoperative ventilation, postoperative dialysis, hypertension and smoking, prolonged operative time, and postoperative hemorrhage.¹⁴ A variety

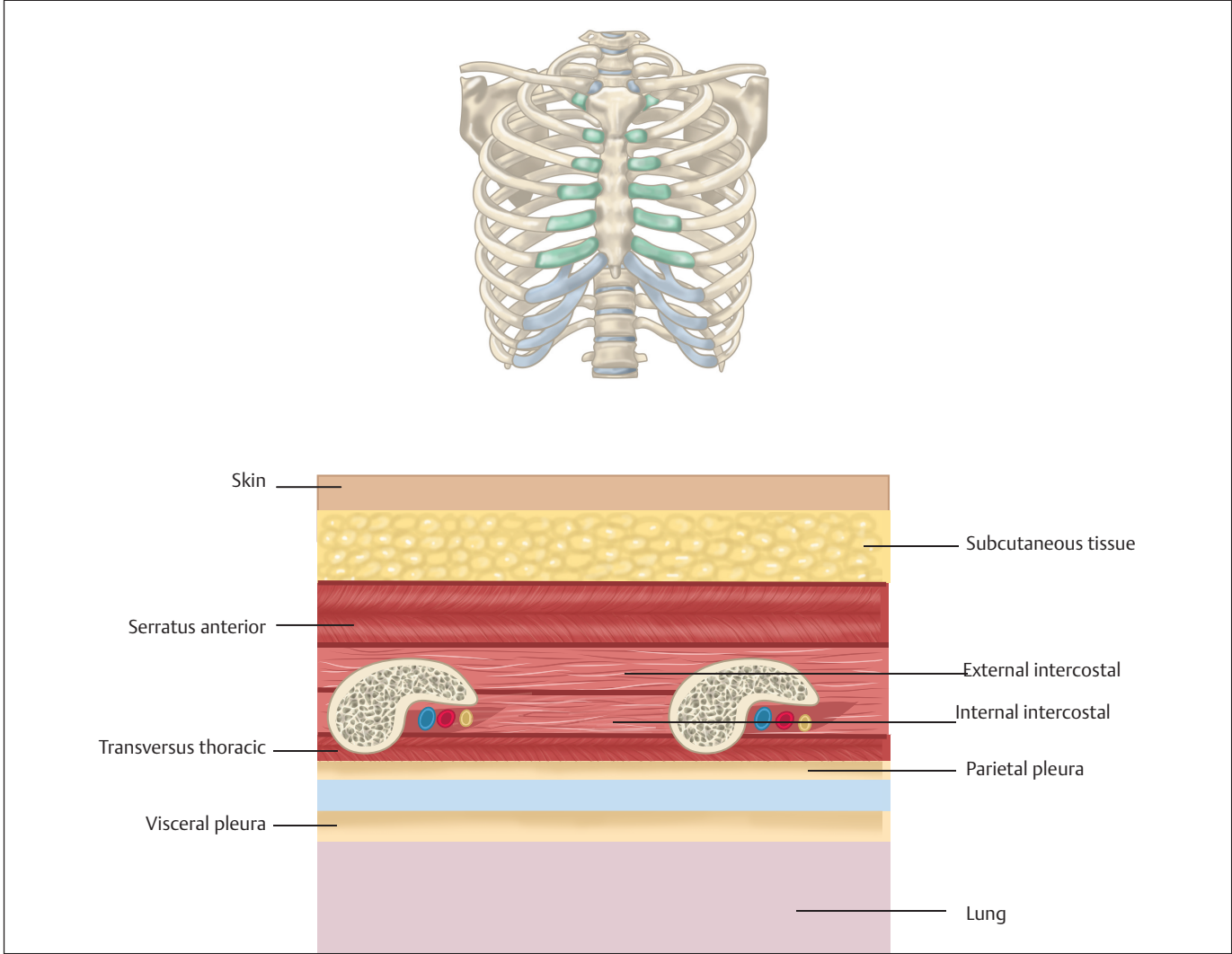


Fig. 1.1 Cross-sectional view of the chest wall.

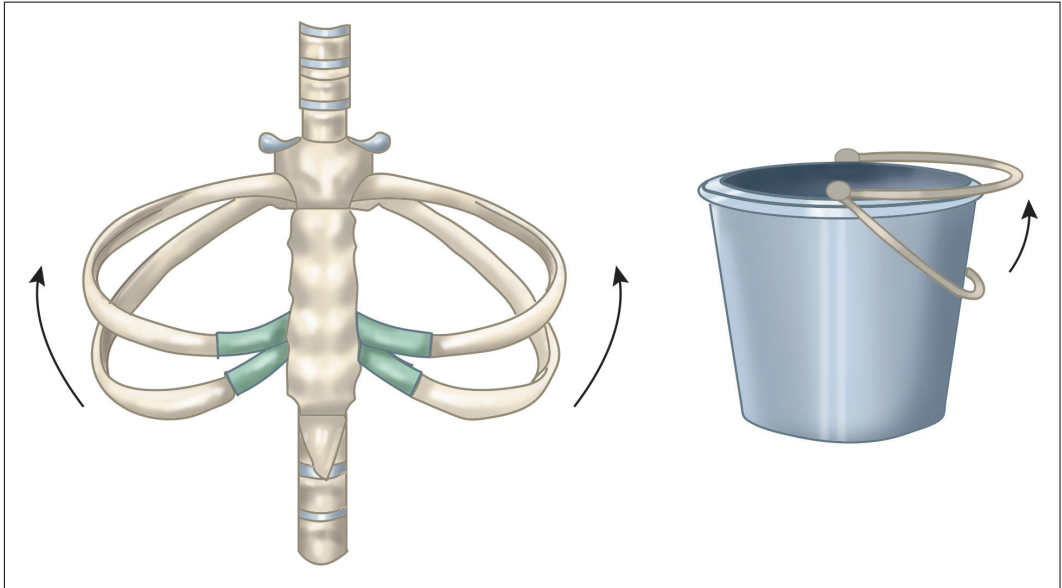


Fig. 1.2 Bucket handle movement of the ribs during inspiration.

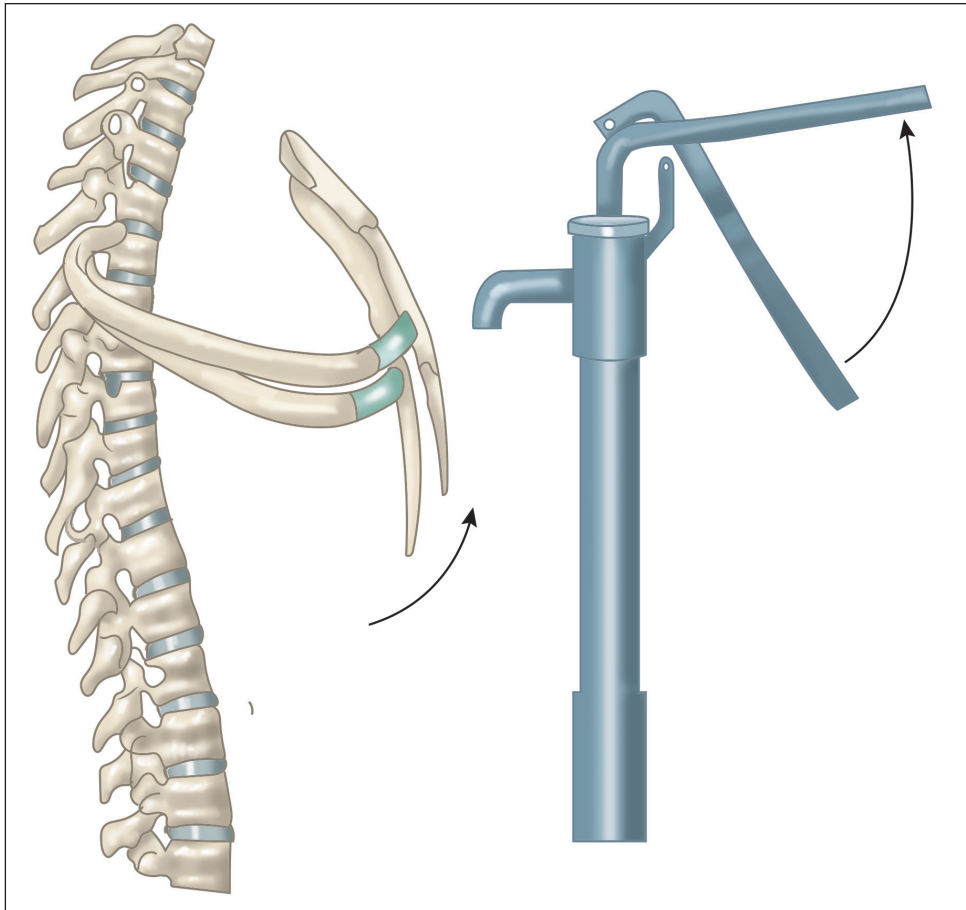


Fig. 1.3 Pump handle movement of sternum during inspiration.

of microbiological organisms have been isolated, the most common being *Staphylococcus aureus* (Firmin and Wood 1987). It is believed that the infection plays secondary role to other causes of etiology of the dehiscence. The possible role of disruption of blood supply to the sternum resulting from increased use of internal mammary arteries for cardiac revascularization is unclear (Grmoljez and associates 1975; Hutchingson and associates 1975). The periosteal blood supply to the sternum is well connected through adjacent soft tissue to the intercostals, and care should be taken to minimize periosteal stripping while harvesting the coronary arteries.

Exposure of Pacemaker

Pacemaker unit consists of lead and pulse generator. The leads are endocardial or epicardial. The epicardial leads are placed through thoracotomy approach, and endocardial leads are placed either through cephalic–subclavian vein approach or through direct subclavian puncture. The pocket to place pulse generator is designed near to point of venous entry. This is generally subcutaneous pocket in infraclavicular region at junction of middle and lateral thirds of the clavicle. The exposure for implanted lead or pulse generator is due to thin skin cover, infection, hematoma formation, etc. If exposed, it ideally needs to be repositioned. The best way

is to take incision away from the pocket so that suture line does not fall over the pulse generator unit. Do not create big pocket, as this can increase chances of hematoma as most of these patients are on blood thinners. Appropriate hemostasis and layered closure are key to success.

Postoncological

Neoplasms

The primary chest wall neoplasms are uncommon and slow growing. The soft tissues of the chest are the major source for chest neoplasms. More than 50% are malignant in nature. Most common primary malignant chest wall tumors being chondrosarcomas, osteosarcoma, and malignant fibrous histiocytoma.¹⁵

Most common primary benign chest wall tumors are the osteochondromas, fibrous dysplasias, and desmoids.¹⁶ Involvement of the chest wall may also be due to metastasis or local spread of tumors of the lungs, pericardium, or even carcinoma breast. All of these tumors require wide excisions.

Radiation Necrosis

Radiation necrosis of the ribs may occur when the chest wall receives radiation for tumors of the breast or chest. The bone may suffer irreversible vascular damage and results in

necrosis. The presenting complaint is usually discharge of pus and bone fragments. The management involves debridement of the necrotic bone and flap cover.

Traumatic Chest Wall Defects

Traumatic chest injuries are generally a result of the road traffic accidents and require urgent management of the airway. The trauma team or the thoracic surgeon is more often involved, and the role of plastic surgeon is limited to providing soft tissue coverage of the defect.

Postburn Chest Wall Defects

Deep thermal burns involving the chest wall if not treated adequately can lead to progressive contracture of the scar ultimately leading to deformities of the chest like kyphosis. These burns should be treated in acute stage with skin grafts and postoperative splintage to prevent the deformity. However, full-thickness chest wall defects following electric burns will require prompt, secure, and stable repair. Immediate reconstruction with flaps, for example, local latissimus dorsi flap, is better than skin graft in such situations. If the defect is located at the upper chest accompanied by the costal bone exposure, the cervicothoracic flap has been described for reconstruction.

In late stages, the goals of reconstruction are aimed at complete release of contracture to prevent or correct the deformity especially of the female chest. The options for resurfacing after scar release are Z or V-Y plasty, skin grafts, local rotation or transposition flaps, muscle flaps like latissimus dorsi, free flaps or tissue expansion, or combined utilization of these methods. The principles of reconstruction include complete scar release by inframammary incision so as to preserve breast tissue and preservation of the sensory nerves to breast when surgery is performed around lateral chest wall.

Use of custom-made pressure garments along with regular exercises and postoperative splinting is recommended to prevent disfigurement and maintain range of motion after surgical treatment.

Infections

Empyema

Empyema is collection of pus in pleural cavity due to infection, though bacterial pneumonia is the most common cause, but chest surgeries and trauma are the surgical causes. Pleurisy (chest pain when breathing), dry cough, fever with chills, and shortness of breath are the symptoms. X-ray chest and computed tomography (CT) scan can demonstrate fluid in pleural spaces. Ultrasound is used to localize the pus pocket. The treatment options include drainage of pus percutaneously using a needle (thoracocentesis), intercostal drainage, or in more complex cases, video-assisted thoracic

surgery (VATS) may be required to debride the area and drain the pus. Open decortication, whereby the pleural peel is removed, is sometimes required.

Osteomyelitis

Infection of the ribs may be caused by tuberculosis or other bacterial infections. Chronic infection of the ribs may be predisposed by surgery and radiation. The management requires thorough debridement and flap cover if the ribs are exposed.

Bronchopleural Fistulas

This results from communication of the mainstem, lobar or segmental bronchus with the pleural cavity. The most common cause is postpneumonectomy or lobectomy followed by infections. The treatment for small (< 5 mm) bronchopleural fistulas¹⁷ is bronchoscopic-guided placement of glue or coils, etc., or using stents to bypass the opening in the lung. For bigger defects or for the stump dehiscence of the bronchus, soft tissue flap cover is the best option.¹⁸ The most commonly used flaps are the serratus anterior, pectoralis major, and latissimus dorsi for the upper half of the lungs, but for more inferior part of the lungs the flaps of choice are usually diaphragm, intercostal muscle flap, or omental flap.

Dr Leo Eloesser,¹⁹ described the Eloesser flap, which was a tubeless one-way valve, to drain chronic pleural effusions without the need for extensive thoracoplasty. Clagett and Geraci,²⁰ for the treatment of postpneumonectomy empyema described formation of open window in the lateral aspect of the chest and irrigation with antibiotic solution and later closer of the chest cavity once granulation tissue was seen. However, both these procedures are of historical interest only with newer antibiotics to control the infections and development of various modalities of closed pleural drainage.

Indications for Chest Wall Reconstruction

The common indications for chest wall reconstructions where a plastic surgeon is required include the following. In all cases, bony reconstruction may not be required and just soft tissue reconstruction may suffice.

Only Soft Tissue Reconstruction

- Postinfective defects.
- Osteoradionecrosis.²¹
- Bronchopleural fistulas.

Bony and Soft Tissue Reconstruction

- Tumor excisions of the chest walls.
- Posttraumatic chest wall defects.

- Postoperative sternal dehiscence.
- Congenital disorders (pectus excavatum, pectus carinatum, and Poland syndrome).

Goals of Chest Wall Reconstruction

In resections of large chest wall segments, reconstruction of rigid chest wall is necessary to prevent physiological flail.²²

Soft tissue coverage is necessary to seal pleural space, protect viscera and great vessels, and prevent infection. To achieve these, chest wall reconstruction should maintain the chest wall integrity; the closure should be airtight, reconstruction should withstand postoperative radiation if needed, elimination of respiratory support, faster rehabilitation, and a better quality of life.

Reconstruction of the Chest Wall

Component Reconstruction

The reconstructive sequence begins with the deepest tissues and proceeds to the most superficial.²³

- **Pleura:** No separate reconstruction is required.
- **Skeletal reconstruction (bone):** Prosthetic materials.
- **Soft tissues (skin and subcutaneous tissues):** Soft tissue flaps.

Skeletal Reconstruction

The sternal, anterior, and lateral chest wall movements are more during respiration as compared to the posterior chest wall hence the indications for reconstruction differ (Box 1.1). Materials used for skeletal reconstruction should be such that they are inert and at the same time give rigid support to the skeletal framework of the chest. This is important to prevent a flail segment. At the same time, a semirigid material like mesh is better integrated with the tissues.

In the *sandwich technique*,^{16,24,25} a combination of both rigid and semirigid material is used with polymethyl methacrylate forming the rigid base and sandwiched between the prolene mesh on either side. This can be *inlay* or *onlay* (Fig. 1.4) depending on the placement of the *bone cement prolene sandwich* over or under the ribs. Onlay results in

better lung expansion, but flap requirement is more and the extrusion rates are higher. The wires are used to fix the bone cement to the ribs as it absorbs chest wall movements better. Prefabricated polymethyl methacrylate ribs prepared in prosthodontic laboratory can be used as an alternative to replace resected ribs. It provides perfect stability and rigidity to the chest wall (Box 1.2).^{26,27}

The future may lie with absorbable semirigid meshes, biointegratable acellular homografts and xenografts, demineralized bone matrices, and bone marrow stromal cells.²⁸ The future of bony reconstruction lies in three-dimensional (3D) alloy implant materials and 3D-assisted surgical virtual mode.²⁹ However, the insertion of prosthetic material to achieve rigid and nonrigid skeletal reconstruction could be associated with more complications including surgical site infection (SSI), wound dehiscence, and possible extrusion of prosthesis especially in high-risk patients.³⁰⁻³² Rigid prosthetic mesh, such as methyl methacrylate, can result in chest wall deformity and chronic pain.³²

As far as we know, an ideal material and technique of reconstruction shall meet the following requirements: (1) high rigidity and stability to avoid chest wall floating; (2) keep in body for long time without rejection reaction and likelihood of infection; (3) easy to cut, shape, and fix; (4) be convenient for sterilization; and (5) radiolucency to make an anatomical reference to do a better follow-up and identify a possible local neoplastic relapse.²⁷

Soft Tissue Reconstruction

The reconstruction of the soft tissues can range from primary closure, skin graft, local flaps (Fig. 1.5a-c), vacuum-assisted closure, pedicled flaps to perforator, and free flaps. For oncological reconstructions, the requirement of postoperative radiotherapy mandates use of flaps as tolerance of skin grafts to radiation is poor. Use of perforator flaps³³ in combination with alloplastic materials can also be considered as

Box 1.1 Indications for skeletal reconstruction

- Sternotomy
- Anterior and lateral thorax
 - Excision of 3 or more ribs
 - Full-thickness defect of 5 cm or more
- **Posterior thorax:** Full-thickness defect of 10 cm or more

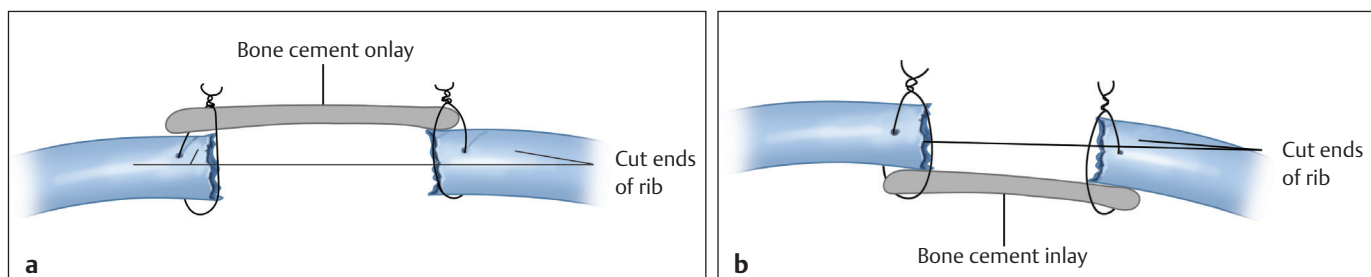


Fig. 1.4 Bone cement with mesh (sandwich) may be fixed using (a) onlay technique (b) inlay technique.

Box 1.2 Materials used for bony reconstruction of chest²⁷

- Semirigid materials
 - Autologous
 - Fascia lata
- Synthetic
 - Absorbable polygalactin mesh
 - Nonabsorbable Prolene (Marlex), polytetrafluoroethylene (Goretex)
- Rigid materials
 - Autologous bone
 - Synthetic
 - Polymethyl methacrylate (PMMA)
 - Titanium
 - Silicone
 - Acrylic
- Sandwich—rigid and semirigid material

a reliable option for full-thickness chest wall defect reconstruction (**Table 1.1**).

Median Sternotomy Wound

Classification

Jones et al³⁴ have classified sternal wound dehiscence depending on the depth of infection and stability of sternum (**Table 1.2**). Type 1 is superficial infection and types 2 and 3 involve deeper tissues.

A useful classification system based on timing of presentation, and character of the wound is described by Pairolero and Arnold³⁵ (**Table 1.3**).

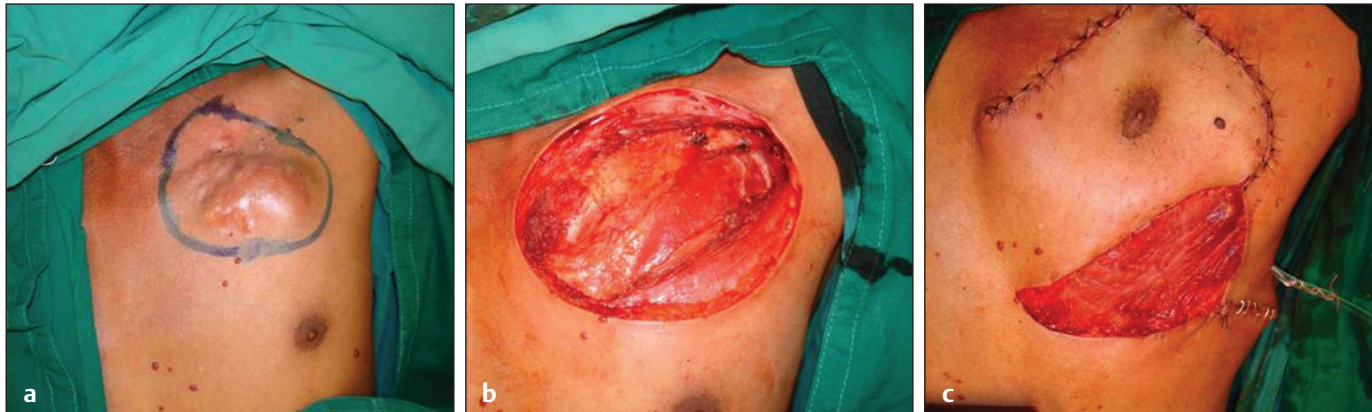

Fig. 1.5 Local flap for coverage of anterior chest wall defect. **(a)** Preoperative marking. **(b)** Defect. **(c)** Local transposition flap based on internal mammary perforators (deltopectoral flap).

Table 1.1 Flap options as per location of the defect

Sternum	Anterior	Lateral	Posterior
Pectoralis major	Latissimus dorsi	Latissimus dorsi	Latissimus dorsi
Latissimus dorsi (Fig. 1.6a–d)	Serratus anterior	Perforator flaps	Trapezius
Vertical rectus abdominis (Fig. 1.7 a–c)	Vertical rectus abdominis		
Omentum (Fig. 1.8 a–f)			
Free flaps—anterolateral thigh flap (Fig. 1.9 a–e), rectus abdominis flap			

Table 1.2 Jones et al classification

Type	Depth	Description
1a	Superficial	Skin and subcutaneous tissue dehiscence
1b	Superficial	Exposure of sutured deep fascia
2a	Deep	Exposed bone, stable wired sternotomy
2b	Deep	Exposed bone, unstable wired sternotomy
3a	Deep	Exposed necrotic or fractured bone, unstable, heart exposed
3b	Deep	Types 2 or 3 with septicemia

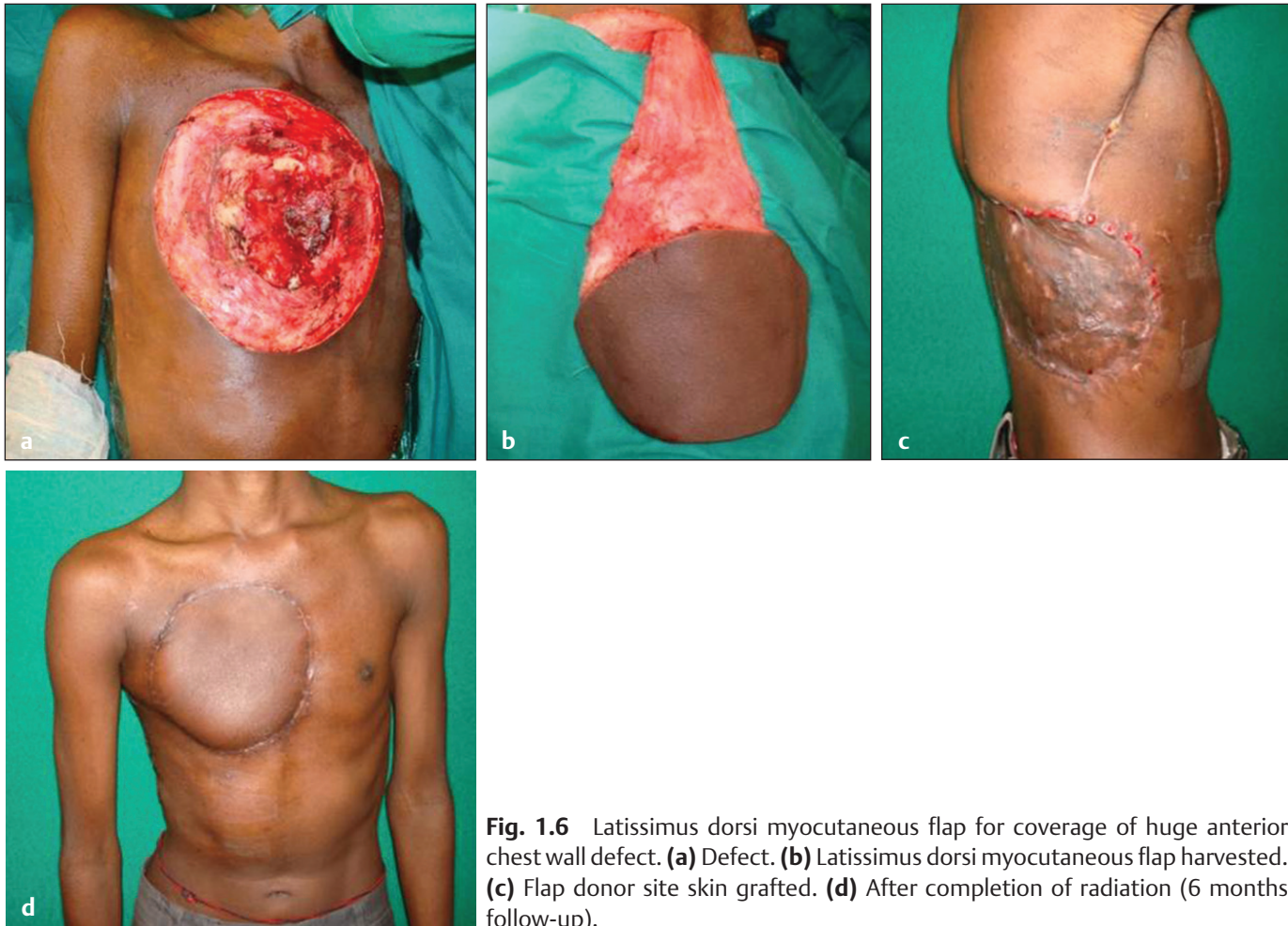


Fig. 1.6 Latissimus dorsi myocutaneous flap for coverage of huge anterior chest wall defect. **(a)** Defect. **(b)** Latissimus dorsi myocutaneous flap harvested. **(c)** Flap donor site skin grafted. **(d)** After completion of radiation (6 months follow-up).

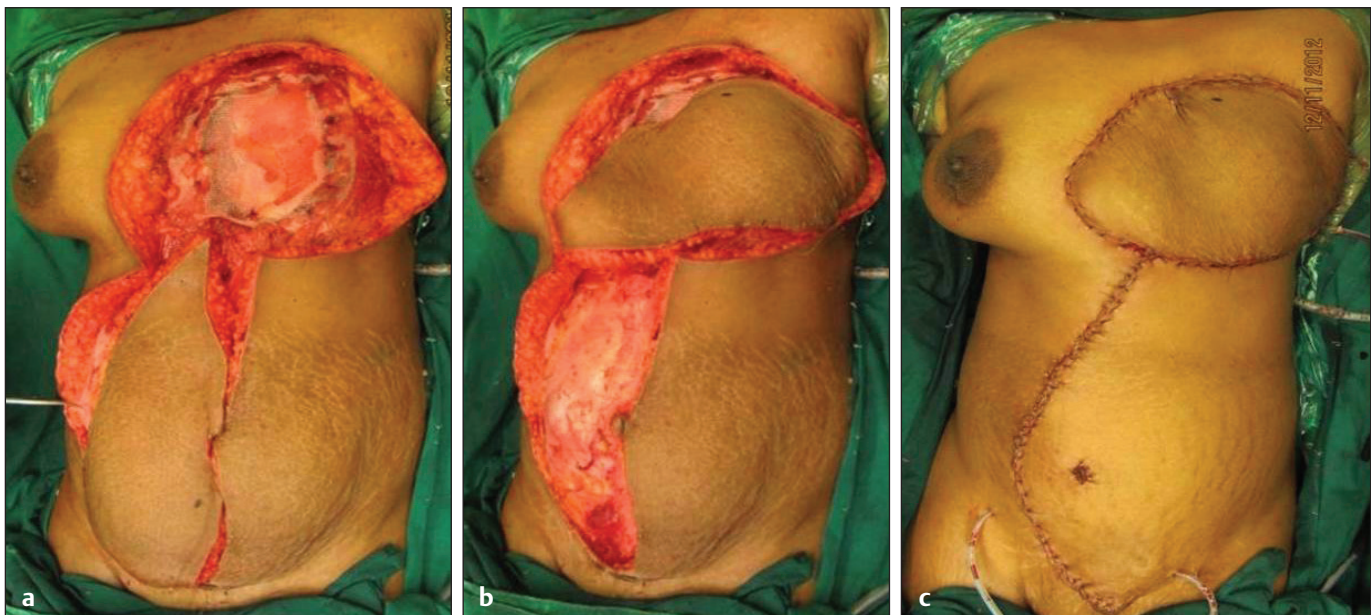


Fig. 1.7 Vertical rectus abdominis myocutaneous flap for anterior chest wall defect. **(a)** Postmastectomy defect skeletal reconstruction done using the sandwich technique. **(b)** The vertical rectus abdominis myocutaneous flap. **(c)** Flap inset complete.

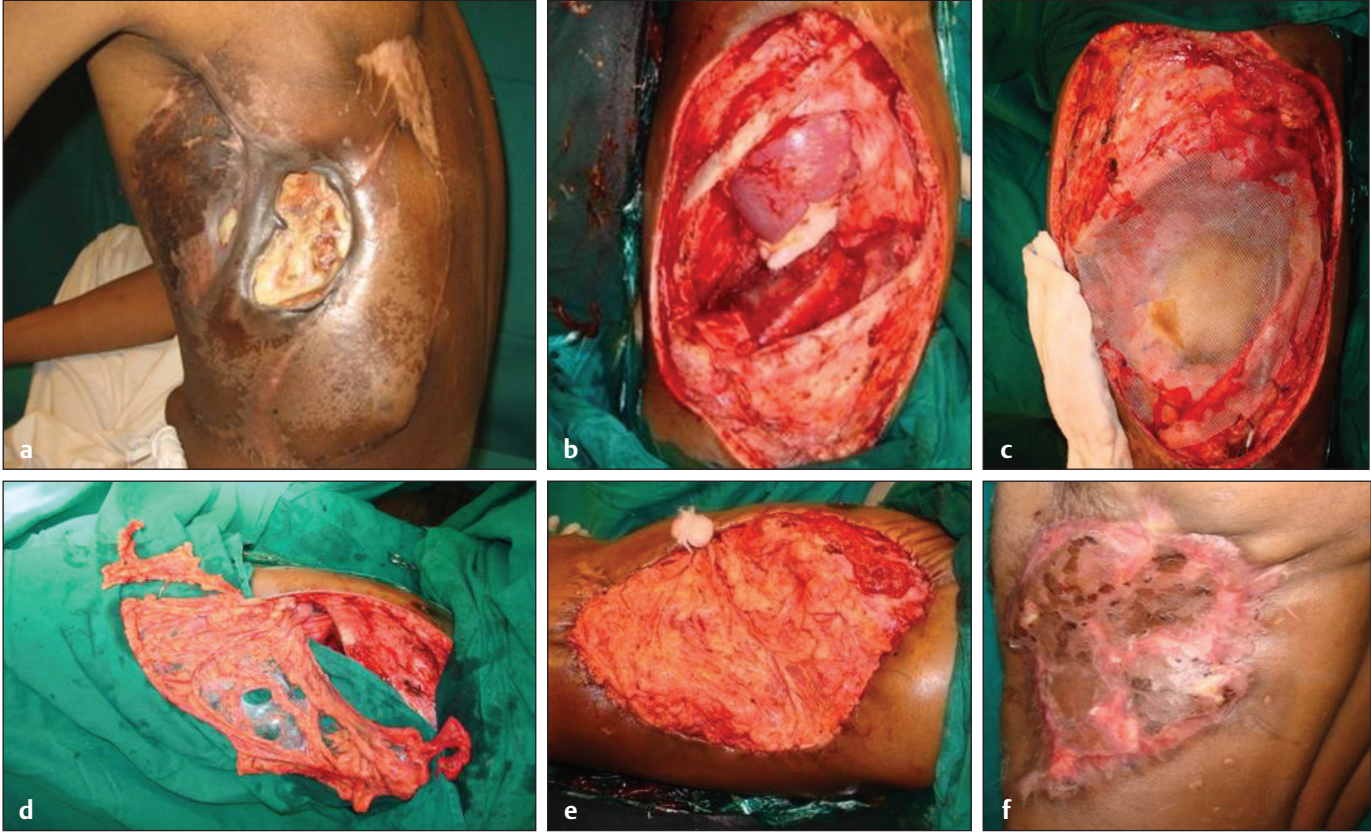


Fig. 1.8 Omental flap for coverage of lateral chest wall defect. **(a)** Multiple surgeries performed. **(b)** Defect of the chest wall. **(c)** Skeletal reconstruction using sandwich technique. **(d)** Omental flap harvested. **(e)** Omental Flap transferred to the thoracic region by making a small rent in the diaphragm. **(f)** Late follow-up after secondary skin grafting.

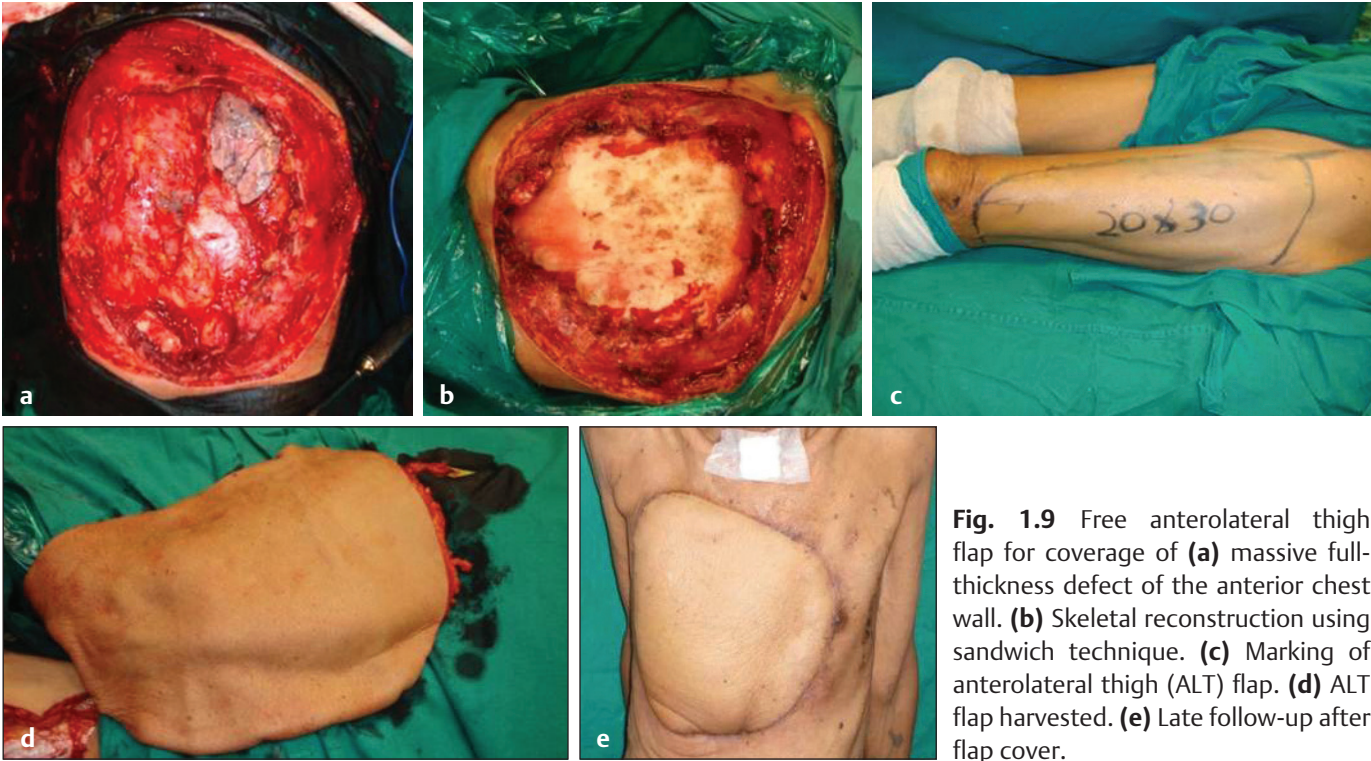


Fig. 1.9 Free anterolateral thigh flap for coverage of **(a)** massive full-thickness defect of the anterior chest wall. **(b)** Skeletal reconstruction using sandwich technique. **(c)** Marking of anterolateral thigh (ALT) flap. **(d)** ALT flap harvested. **(e)** Late follow-up after flap cover.

Table 1.3 Classification of infected sternotomy wounds by Pairolero and Arnold

Type	No. of patients
Type 1 Occurs within first few days Serosanguineous discharge No skin cellulites Mediastinum is soft and pliable Osteomyelitis and costochondritis are absent Cultures are usually negative	11
Type 2 Occurs within first few weeks Purulent discharge Skin cellulites++ Mediastinal suppuration++ Osteomyelitis frequent but costochondritis rare Cultures are positive	84
Type 3 Occurs months to years later Chronic draining sinus track Skin cellulites localized near sinus track Mediastinitis rare Osteomyelitis, costochondritis, or retained foreign body always present Cultures are positive	5
Total	100

Type 1 presents during the first 3 days of coronary bypass grafting. They present with serosanguinous discharge. This is in contrast to type 2 which presents within 2 to 3 weeks of surgery wherein patients present with purulent discharge, skin cellulites, and positive cultures. Type 3 has late presentation—months to years after surgery and is associated with sternal osteomyelitis and costochondritis. They present with single or multiple discharging sinuses.

Preoperative Evaluation and Patient Presentation

The patient can present with variety of scenarios. Patient with frank mediastinitis looks ill and complains of fever, chest pain, breathlessness, rib pain, and discharging sinus. On the other hand, patients may be asymptomatic except for small recurrent discharging sinus over sternum and may present to surgeon on OPD basis. The evaluation of such patients can be divided into clinical, radiological, pathological, and microbiological.

Clinically, one should ask detailed history of coronary artery bypass surgery. What were the vessels used for cardiac revascularization? If both left and right mammary vessels were used, it adds to devascularization of the sternum. History of comorbid conditions like smoking, diabetes

mellitus, prolonged postoperative ventilatory support, need for postoperative dialysis, prolonged operative time, and postoperative hemorrhage should be noted. Patient should also be examined for stability of the sternum and asked about history of sternal wire removal if any.

Radiological investigations include X-ray of the chest and 3D computerized tomography of chest cage. The CT scan provides valuable information about union of median sternotomy, status of mediastinitis, and costochondritis, presence of prior retrosternal collections if any (**Fig. 1.10**).

Pathologically, one needs to evaluate white blood cell (WBC) counts and C-reactive protein levels. Microbiologically, cultures should be sent from the depth of the discharging sinus.

Surgical Treatment Options

The management of the patient should be multidisciplinary in approach. The cardiac surgeon, who did bypass procedure, plastic surgeon, intensivist, and paramedical support team are members of this team. A treatment algorithm can be followed depending on early or late presentation (**Flowchart 1.1**).

Debridement

It is widely accepted that adequate early debridement is the first step in treatment plan of sternal wound infections especially in patients with chronic discharging sinus. In ideal scenario, the primary surgeon should be present

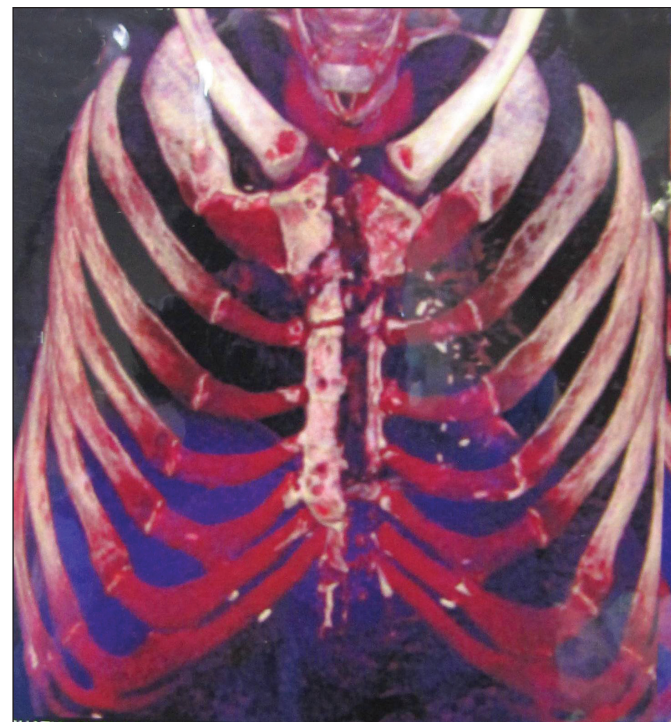
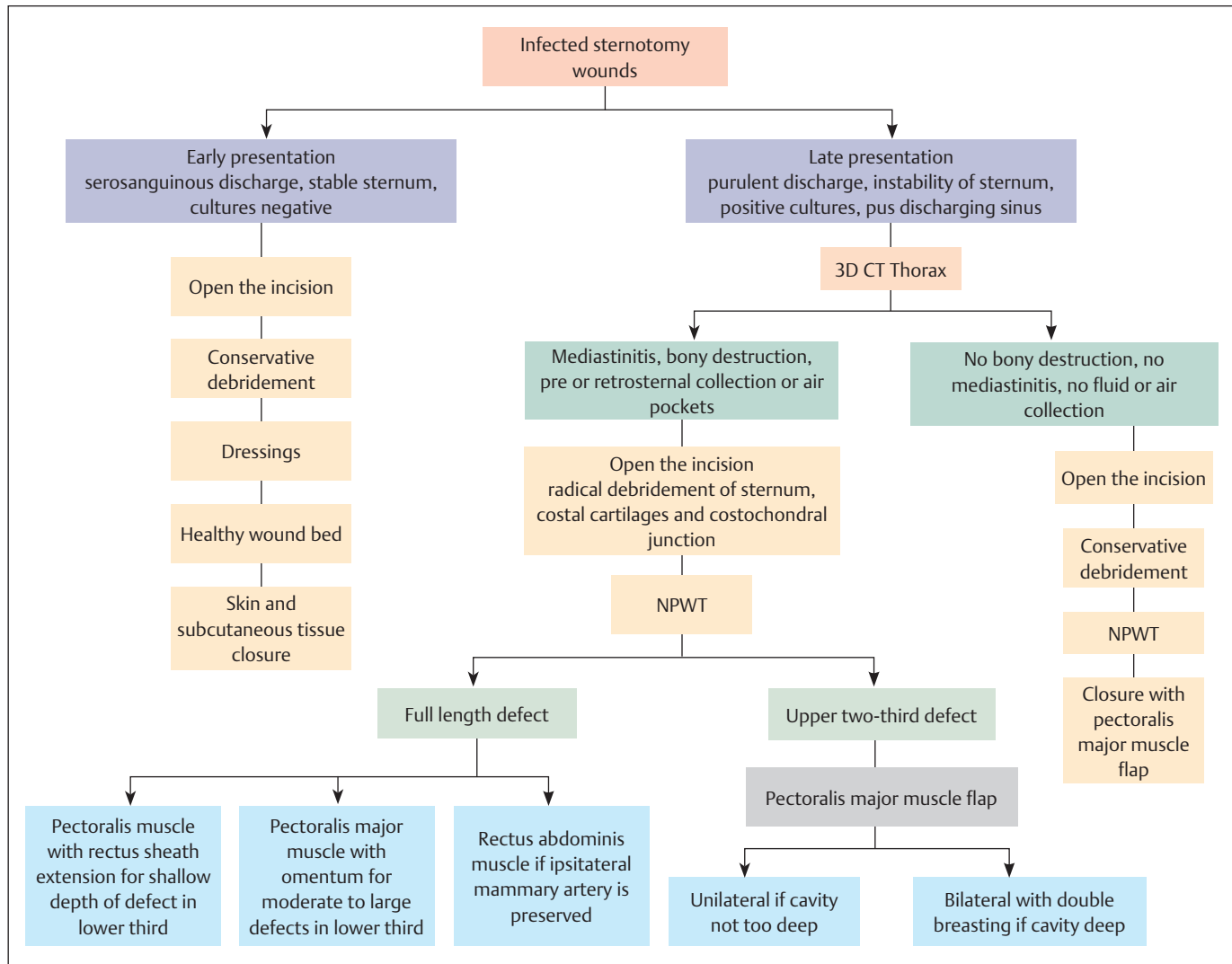


Fig. 1.10 Thoracic CT showing sternal osteomyelitis and destruction.



Flowchart 1.1 Treatment algorithm.

during debridement, but in reality, it is very rare. The extent of debridement is crucial to final outcome of the patient. Instability of the sternum, loose sternal wires, and unhealthy sternal edges are indications for opening of sternal wires. Fibrous adhesions between the sternum and right ventricle should be released with blunt dissection to minimize the risk of laceration to the right ventricle. Nonviable, necrotic margins of the sternum should be debrided. Spontaneous bleeding from bony margins should be the endpoint of bony debridement. In cases of extensive sternal osteomyelitis, costal cartilage excision may be required along with sternal debridement (Fig. 1.11). Intraoperative soft tissue and bone tissue samples must be collected for aerobic and fungal cultures. At the end of thorough debridement, wound is irrigated with saline solution. For patients with minimal sternal bone debridement and with good vascularity of the wound, definitive closure can be done at the time of debridement itself. For patients who have undergone extensive bony debridement, NPWT device can be applied

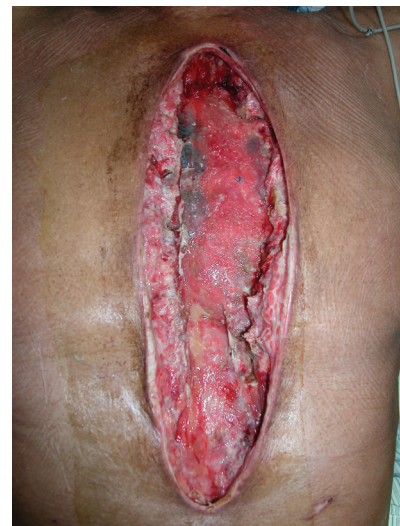

Fig. 1.11 Radical debridement of the sternum, soft tissue, and costal cartilages.

at pressures between 75 and 100 mm Hg on continuous mode. NPWT when used also helps in achieving sternal stability before closure, thus preventing paradoxical chest wall movements. This treatment modality is recommended to bridge the gap between debridement and definitive closure. Once a healthy granulating bed is achieved and patient is hemodynamically stable, the definitive wound closure should be scheduled.

Definitive Closure—Flap Options and Negative Pressure Wound Therapy

Definitive closure is planned as per the wound condition. In cases with approximable sternal edges, sternum is rewired and covered with muscle flap. In the cases, where sternal rewiring is not feasible, muscle flaps or omental flaps are used with subcutaneous tissue and skin closure.

Numerous muscle flaps have been used in the treatment of sternal wound infections. The mainstay of treatment continues to be pectoralis major muscle flaps.

The muscle can be used on either of the pedicle. A turnover pectoralis major can be done provided internal mammary vessel is not used for bypass and internal mammary

perforators are not damaged during debridement. If both coronaries are used for cardiac revascularization, then the muscle can still be used on thoracoacromial pedicle after dividing its insertion to allow medial movement (**Fig. 1.12**). Don't be hesitant to take separate incision to divide its insertion if required (**Fig. 1.13**). The pectoralis muscle can be used unilaterally or bilaterally. Limitation of the pectoralis flap when based on thoracoacromial pedicle is that it cannot cover lower one-third defect. In such cases, the pectoralis major muscle flap can be harvested with the fascia over the rectus abdominis muscle (**Fig. 1.14**) to fill the cavity in lower end of the defector omentum, or rectus abdominis muscle can be used along with pectoralis muscle. When used as bilateral flaps, the pectoralis major muscles can be double breasted (**Fig. 1.15**). Double breasting not only obliterated the dead space but also gives some amount of stability to the sternum. Suction drains are placed both superficial and deep to the muscle flaps before skin closure. The subcutaneous tissue and skin are closed after refreshing the skin edges.

For a full-length larger defect, either a *rectus abdominis muscle flap* or a *pedicled omental flap* is used. The rectus abdominis muscle is usually based on its superior blood

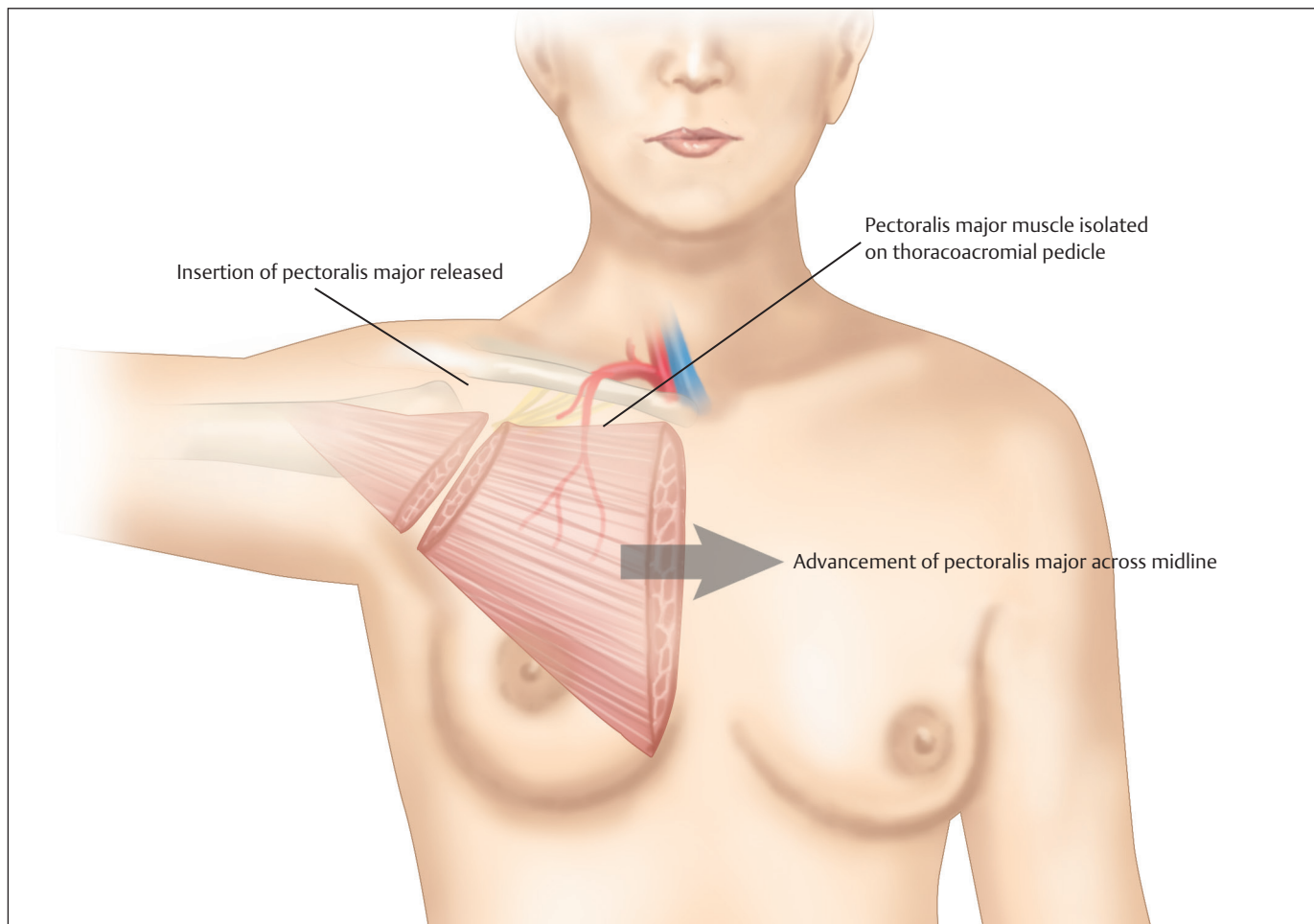


Fig. 1.12 Diagrammatic sketch of pectoralis major muscle flap advancement.

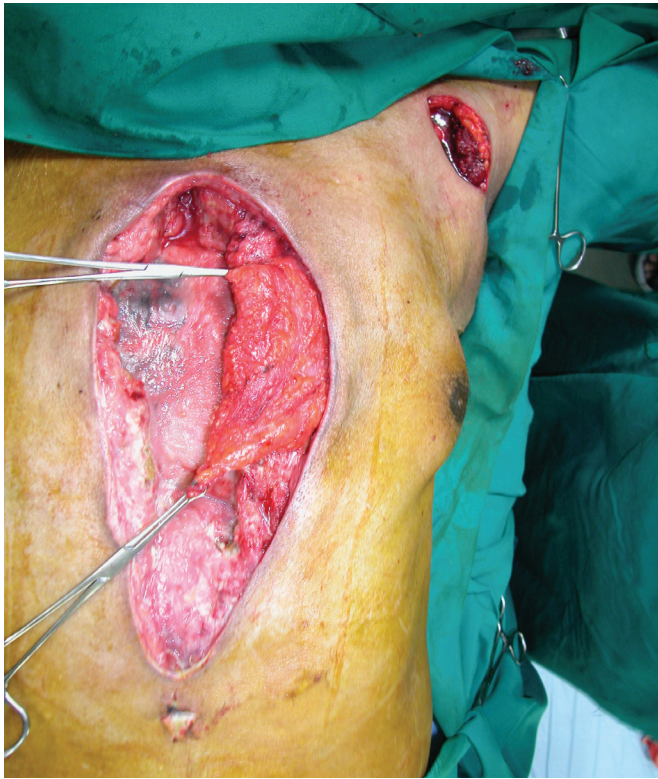

Fig. 1.13 Separate incision in the axilla to divide the insertion of pectoralis major muscle.

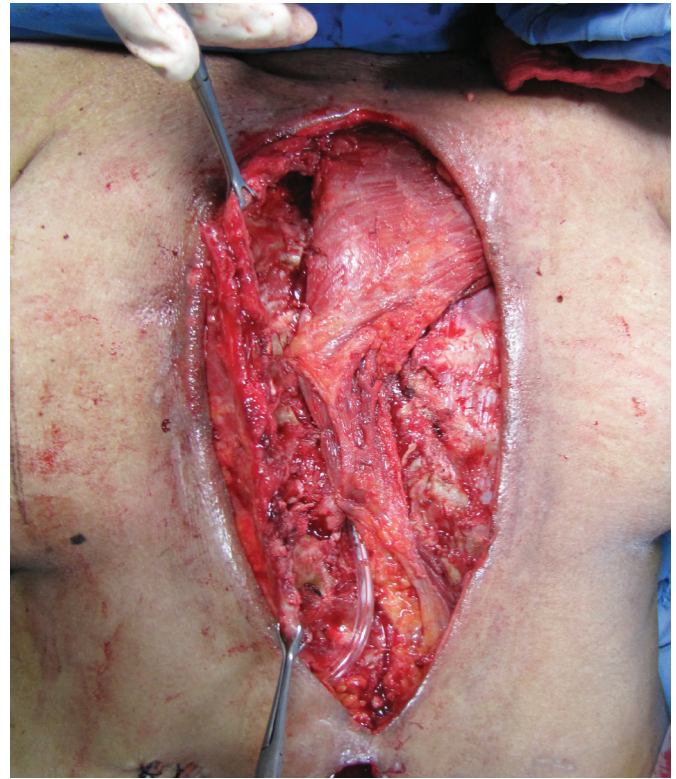


Fig. 1.14 Unilateral pectoralis major muscle flap with rectus sheath extension.

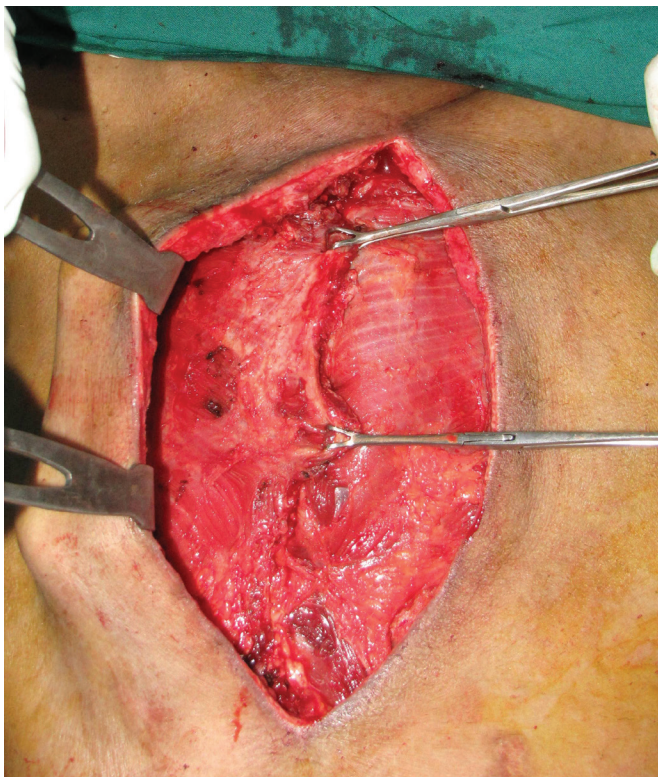


Fig. 1.15 Bilateral pectoralis major muscle flaps with double breasting of pectoral muscles.

supply from the mammary and marginal costal arteries (Milloy et al 1960). The rectus abdominis muscle cannot be used if the bilateral mammary artery is already used for cardiac revascularization.

Omental flap can be fully mobilized on right gastroepiploic artery by dividing the branches to the greater curvature of the stomach. The omentum can either be transposed in anterior mediastinum through subcutaneous tunnel or through a window in the diaphragm. Omentum can be used in conjunction with pectoralis flap so as to obliterate the dead space in the lower part of the defect where pectoralis muscle does not reach (**Fig. 1.16**). The omentum can also be harvested endoscopically. This nullifies the risk of herniation at the epigastric region. The omental flap may be limited in its size if previous abdominal surgery has been done and omentum used intra-abdominally.

The latissimus dorsi muscle can also be used. It is mobilized by dividing its humeral insertion so as to reach beyond midline.

In postoperative period, drains are removed after drain output reduced to less than 30 mL per day. Patients are advised to use chest belt with sternal support for 6 weeks. Limited shoulder abduction is advised for 2 weeks after sternal closure if pectoralis muscle flap is used. Antibiotic therapy is given as per culture sensitivity reports. Patients with positive bone culture reports are prescribed sensitive antibiotics for 6 weeks by intravenous route and/or oral route.

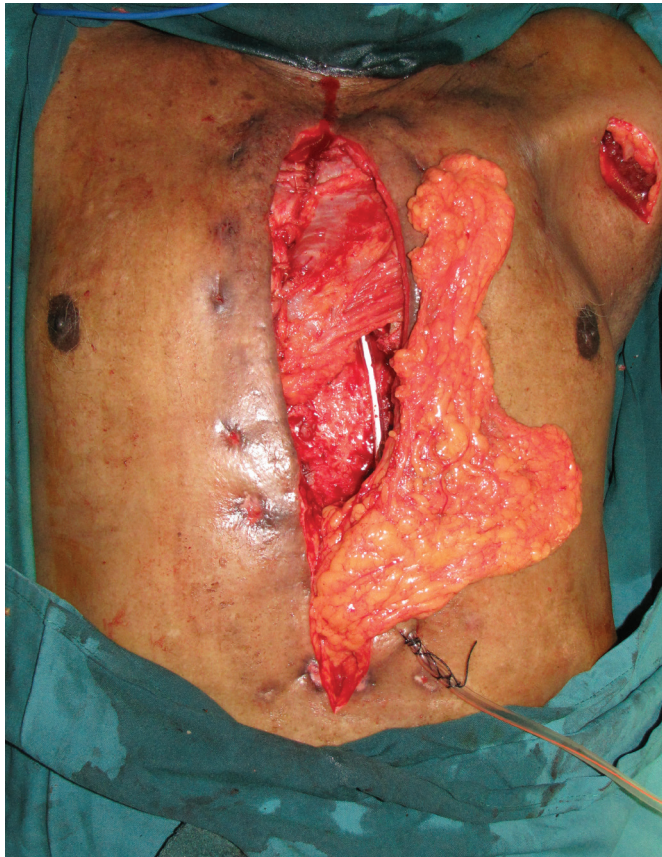

Fig. 1.16 Unilateral pectoralis muscle flap with omental flap.

Congenital Chest Wall Deformities

Reconstruction of congenital chest wall deformities can be very challenging. Manifestations of these conditions may be incomplete, possibly with each component of the chest wall affected in being weakened, deformed, or missing. Consequently, management needs to be individualized. Chest wall abnormalities are largely hypoplastic anomalies, whereas breast abnormalities are usually hyperplastic.

Embryologically, according to anatomical sites, congenital chest wall deformities can be characterized as follow³⁶:

- **Sternum:** Pectus excavatum, pectus carinatum, cleft sternum.
- **Ventral body wall:** Ectopia cordis, pentalogy of Cantrell.
- **Thoracic musculature:** Poland syndrome.
- **Breast:** Supernumerary breast, congenital absence of the breast, tuberous breast, gynecomastia.

The most common chest wall deformities are pectus excavatum (88%) and pectus carinatum (5%).³⁷ Only pectus excavatum, pectus carinatum, and Poland syndrome will be discussed in detail in this chapter.

Embryology

Formation of axial skeleton of the chest wall begins by the third week of intrauterine life. The skeleton, muscle, fascia, and skin are derived from mesodermal somites close to the notochord. The trunk develops from the union of the ectodermal neural crest and the paraxial and lateral plate (somatic layer) mesoderm during the fourth week of gestation. Forty segmental tissue blocks along the neural crest caudal to the head region, known as somites, differentiate into two parts: the dorsolateral somatic cells are called the dermomyotome, and the ventromedial cells are known as the sclerotome. The dermomyotome eventually forms the musculature of the trunk, and the sclerotome develops into the skeletal framework. Most skeletal muscles are fully developed by birth³⁸ (**Fig. 1.17**).

The ribs and transverse processes of the thoracic vertebrae are derived from sclerotomic cells of the paraxial mesoderm. The sternum arises from paired longitudinal concentrations of mesenchymal tissue, the sternal bars, which are separate from the ribs, in the sixth week of development. These are formed on either side of the midline (**Fig. 1.18**).

Pectus Excavatum

Introduction

Pectus excavatum (Latin *pectus*, breast; *ex*, out of; *cavare*, to hollow out) is a disorder characterized by depression of the sternum that may be asymmetric in as many as 50% of cases.³¹ It has also been termed funnel chest and trichterbrust. The deformity usually involves the anterior thoracic cage below the sternal angle, with depression of the middle (body or gladiolus) and lower (xiphoid) sternum, and an associated incurving of the lower costal cartilages that attaches to these segments.

Clinical Profile

Incidence of the anomaly is between 1 in 1,000 and 8 in 1,000 live births³⁹ with a male- to- female ratio ranging from 3:1⁴⁰ to 9:1.⁴¹ About 95% of cases occur in Caucasian patients.

The mechanism and cause of pectus excavatum have not been established. One physical mechanism commonly described is a disproportionate overgrowth of the costal cartilages that pushes the sternum posteriorly, but more recent CT studies have cast doubt on this theory. Nakaoka and colleagues⁴² demonstrated that in pectus excavatum patients, the costal cartilage lengths relative to the adjacent rib were not longer than in healthy control patients. Another mechanism proposed is an abnormal tethering of the sternum to the diaphragm posteriorly.⁴³ Alternatively, a relative weakening of the costal cartilages could be the culprit, which could explain the association of the deformity with other musculoskeletal abnormalities such as scoliosis, Marfan's syndrome, Ehlers-Danlos syndrome, and osteogenesis imperfecta.⁴⁴ There is a genetic predisposition supported

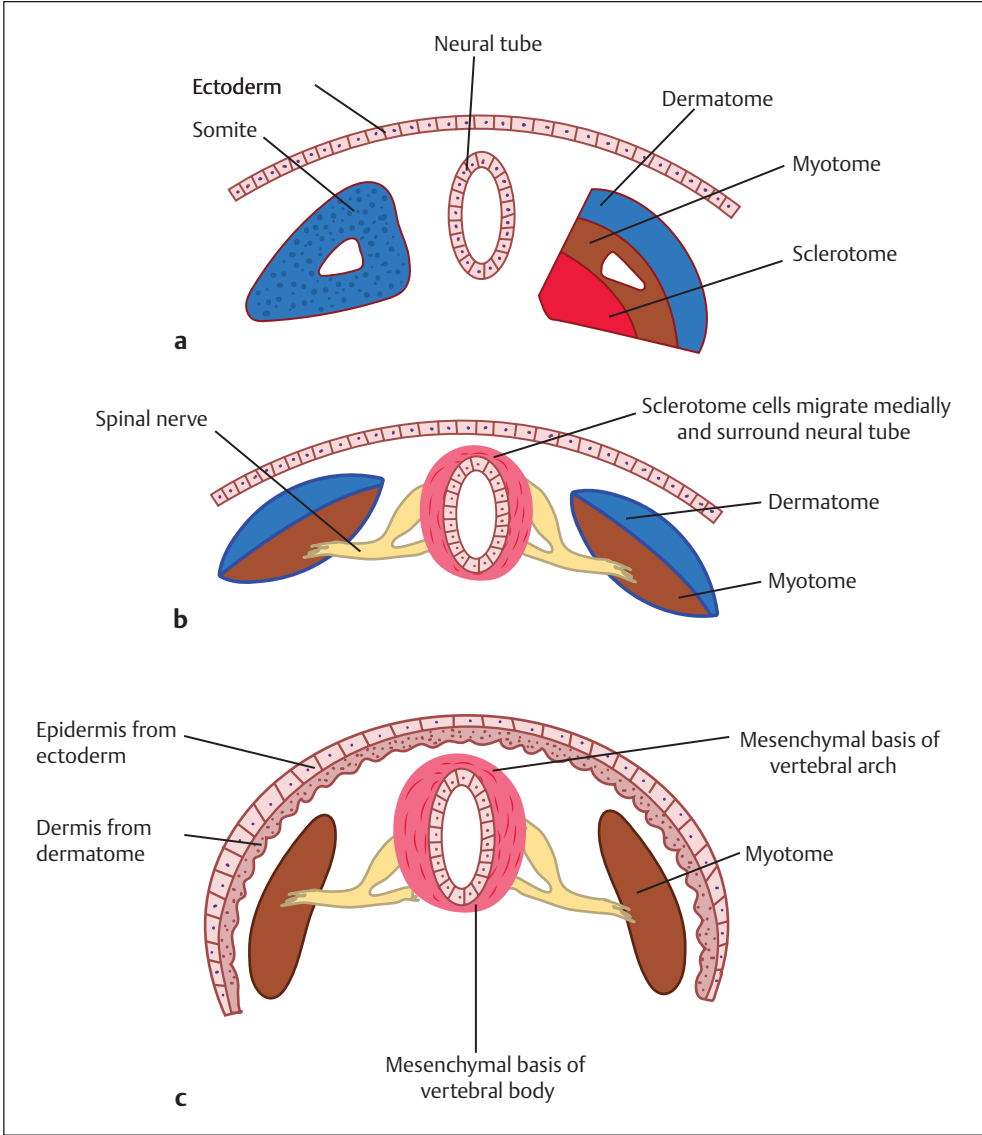


Fig. 1.17 (a–c) Migration and differentiation of paraxial mesoderm into somites and various components of the chest wall.

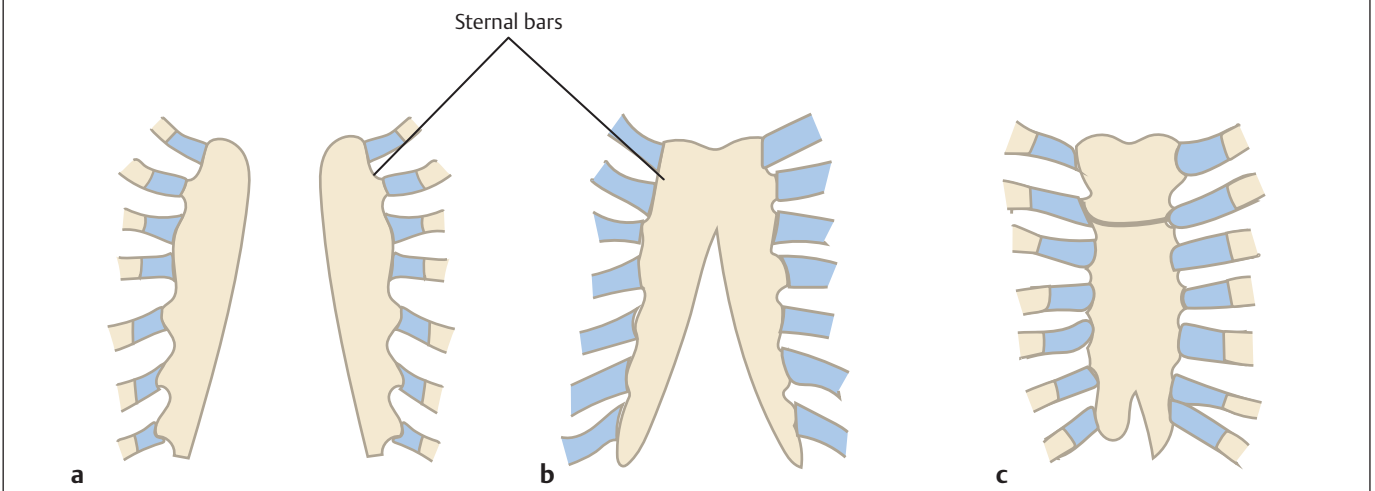


Fig. 1.18 Development of the sternum. **(a)** Sternal bars develop one on each side of the midline. **(b)** Fusion starts in a cephalocaudal fashion with manubrium fusing first. **(c)** Fusion of the complete sternum is over by 10 weeks of intrauterine life.

by roughly 40% of patients having a family member with a chest wall deformity.

Clinical Presentation

The presentation can vary from being asymptomatic with a subtle depression to a major cavity causing severe displacement of lungs, mediastinum, and even the spinal column. The commonest appearance is symmetric depression of the inferior two-thirds to three-fourths of the sternum with extension to the costal cartilages, which, along with the xiphoid may be distorted. The deformity may be described as symmetric or asymmetric with a deeper depression on one side of the sternum. The deformity may be localized (cup-shaped), diffuse (saucer-shaped), or long and unilateral (grand-canyon type).

Pectus-related cardiopulmonary dysfunction is a critical issue in assessment of the severity of the deformity and indications for repair. Pulmonary function testing (PFT), CT or magnetic resonance imaging (MRI) of the chest, and a cardiac evaluation to include electrocardiogram and echocardiogram are a routine part of the evaluation for a patient with pectus excavatum. A thoracic CT scan or MRI allows the physician to grade the severity of the deformity by calculating the Haller or pectus severity index (PSI) that uses the internal measurements of the transverse and anteroposterior dimension at the deepest point of the deformity.⁴⁵ Normal value ranges from 2.5 to 3.25. The more severe the deformity, the higher is the PSI.

Treatment

Asymptomatic patients with mild deformity (Haller index < 3.25) are encouraged to perform deep breathing with 5 to 10-second breath-holding as tolerated, and to continue aerobic activities. Surgical correction of pectus excavatum is offered to those patients who are interested in attempting to improve their exercise tolerance. Most surgeons agree that surgical correction is recommended if the patient has two or more of the following features⁴⁶:

- **Compression abnormalities:** chest CT or MRI showing cardiac or pulmonary compression with a Haller index of 3.25 or greater.
- **Pulmonary abnormalities:** Restrictive lung disease by PFT evaluation.
- **Cardiac abnormalities:** Cardiac compression, mitral valve prolapse (MVP), or conduction abnormalities.
- **Performance abnormalities:** Exercise intolerance, lack of endurance, and shortness of breath on exertion.
- **Recurrence:** Following a surgical procedure.

The optimal age for repair is 10 to 14 years of age because at this time the rib cage is more malleable, thus allowing for rapid recovery, better results, and a lower recurrence rate, as the metal bar that is used to correct the deformity remains in place during musculoskeletal maturation.

Conservative

The vacuum bell may represent a future method of treating selected pectus excavatum patients noninvasively. The concept of applying vacuum to the chest wall to correct deformities was initially described more than 100 years ago.⁴⁷ In 2005, Schier and colleagues⁴⁸ introduced the use of this device with 60 patients (age 6.1–34.9 years, median 14.8 years). After 1 month, 85% achieved 1 cm of sternal elevation, but only 20% had complete correction after 5 months. Longer-term results were published by Haecker⁴⁹ in 2011. One conclusion by Haecker was that results were better for patients with mild and symmetric pectus excavatum.

Operative Procedures

Multiple surgical techniques have been described for the repair of pectus excavatum. Perhaps the most popular approach was first described by Ravitch⁵⁰ and modified by Shamberger and Welch,⁵¹ Haller et al,⁵² and Fonkalsrud et al.⁵³

Ravitch Procedure

The surgical repair involves various modifications of the original procedure described by Brown and modified by Ravitch.^{50,52,53} A transverse thoracic or more commonly, a vertical midline incision is made. Pectoralis muscle is elevated to expose the depressed sternum and costal cartilages from at least T3 to T7. The perichondrium is scored longitudinally, and the deformed cartilages are resected either partially or completely with preservation of the perichondrial sheaths. The xiphoid may require division from the sternum if it is expected to protrude after correction. An anterior table, wedge-shaped, sternal osteotomy is performed at the cephalad transition from the normal to the depressed sternum near the level of the insertion of the second or third costal cartilages. For an optimal cosmetic result, the osteotomy may need to be at an angle if the sternum is rotated. The posterior aspect of the sternum is dissected free, elevated, and fractured by upward traction. The osteotomy is closed with nonabsorbable sutures. A drain is positioned below the muscle flaps. The muscle flaps are sutured back into position and the incisions are closed (**Fig. 1.19**).

Minimally Invasive (Nuss) Procedure

In 1998, Nuss described a new approach to pectus excavatum repair involving placement of a retrosternal bar designed to push the sternum forward (without cartilage resection or sternotomy), allowing remodeling of chest wall cartilage and bone.⁵⁴ The chest is measured transversely with a paper ruler from bilateral points located slightly medial to the anterior axillary line. The bar length selected is 2.5 cm less than this measurement. Lateral incisions are made and tunnels are created to the planned entrance and exit sites, which are medial to the greatest apex. All this is done under direct thoracoscopic visualization to avoid

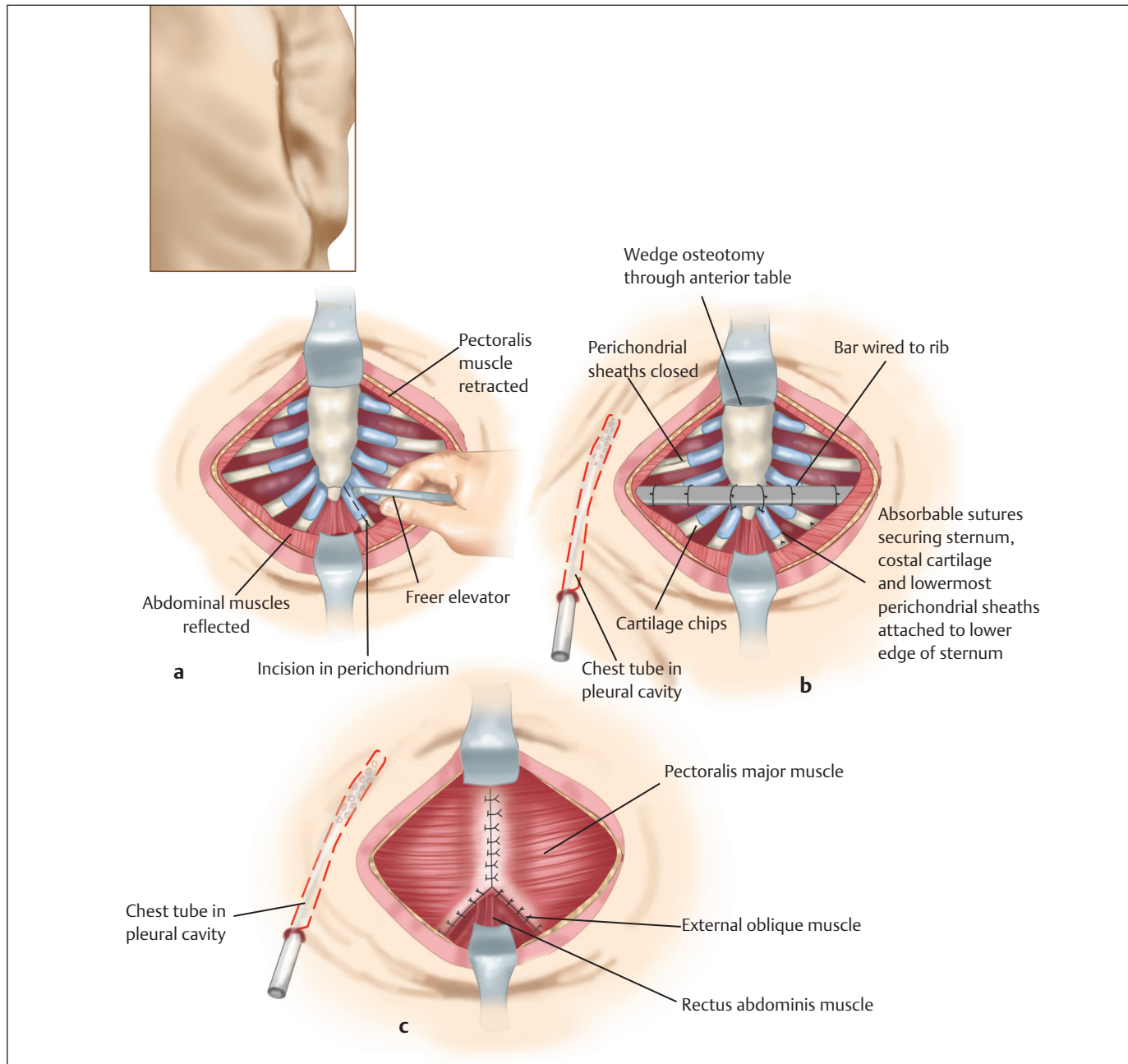


Fig. 1.19 Pectus excavatum repair, modified Ravitch procedure. **(a)** Transverse inframammary incision is made. **(b)** A transverse wedge osteotomy is made across the lower anterior table of the sternum at the desired level. The xiphoid and lowermost perichondrial sheaths are reattached to the sternum along with autologous costal cartilage grafts into the open perichondrial sheaths. **(c)** Drainage chest tube is placed into the right pleural cavity.

injury to the heart, lungs, and great vessels. Using an umbilical tape, the Nuss bar that has previously been measured and bent is placed, concave side forward, from one pleural cavity, across the mediastinum anterior to the pericardium, to the other pleural cavity, and then “flipped” concave side down (**Fig. 1.20**). The bar is maintained for 2 to 3 years to decrease recurrence rates. The bar is typically removed as

an outpatient procedure (**Figs. 1.21–1.26**). Recurrence of the deformity may occur in 8% of patients.

Endoscopic Correction

Since corrective surgery may require a long vertical midline incision that is prone to scar hypertrophy, especially in the Indian patient, endoscopic assistance is of immense value

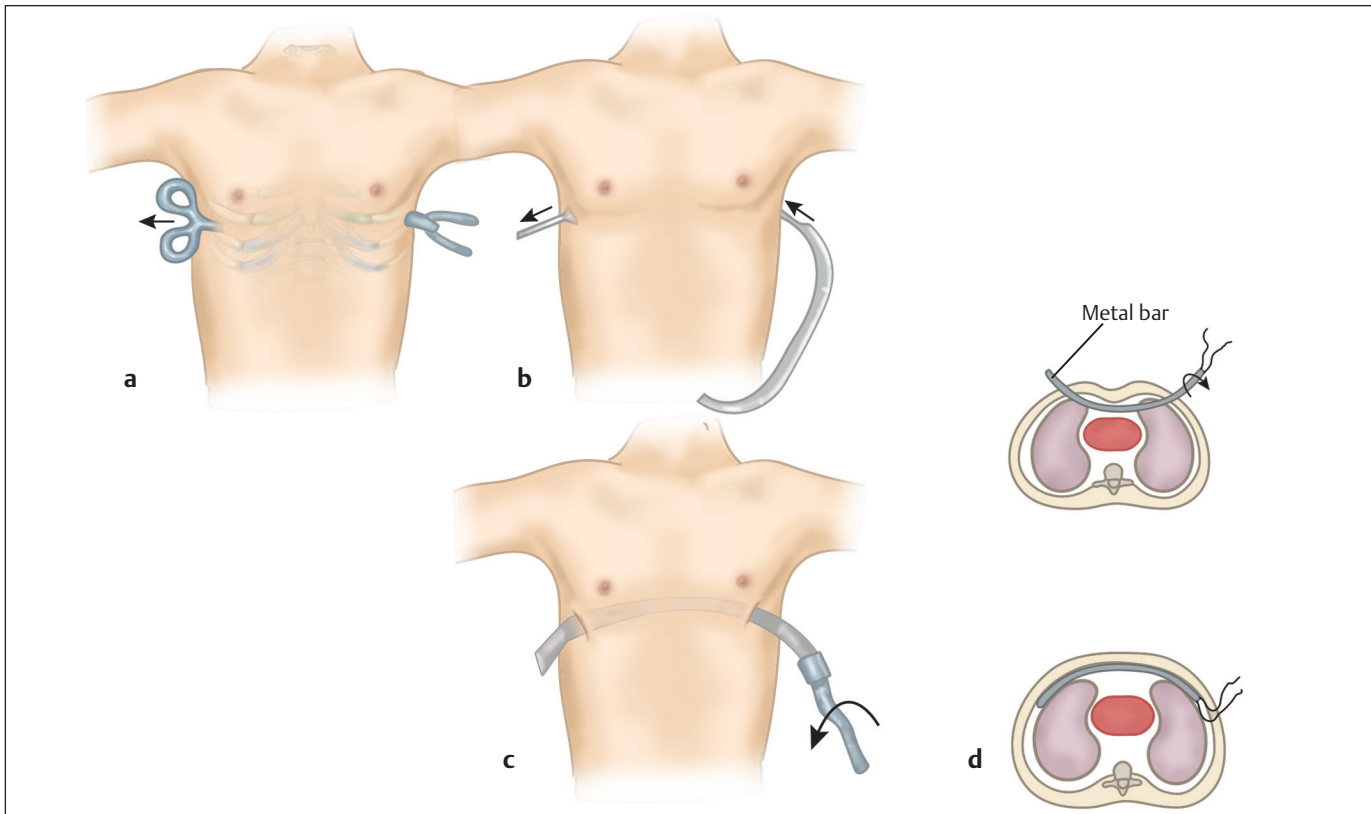


Fig. 1.20 Pectus excavatum repair, Nuss technique. **(a)** A long curved Kelly clamp advanced across the mediastinum deep to the sternum. **(b)** Convex steel bar being guided into the substernal tunnel with use of umbilical tape to keep it on track. **(c)** Pectus bar positioned deep to sternum with concavity facing posteriorly and umbilical tape still attached to one end. **(d)** Diagram shows steel bar in the process of being flipped over.

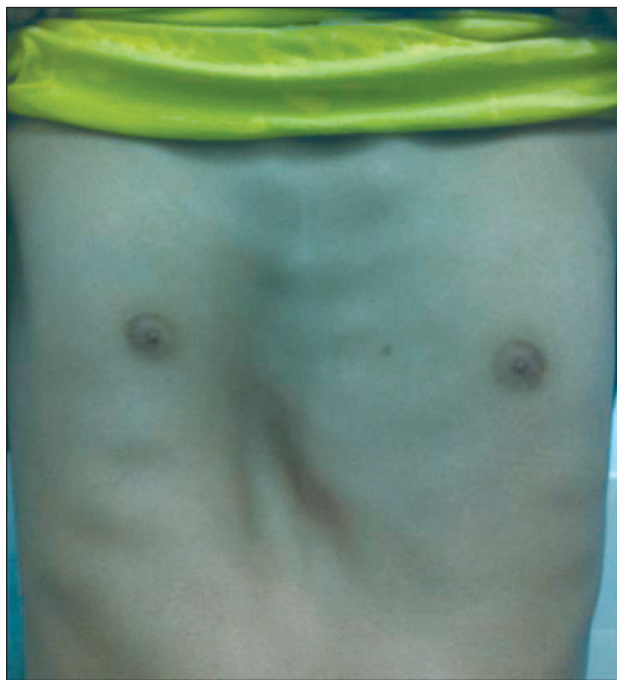

Fig. 1.21 A pectus excavatum deformity of the right middle and lower anterior chest wall.

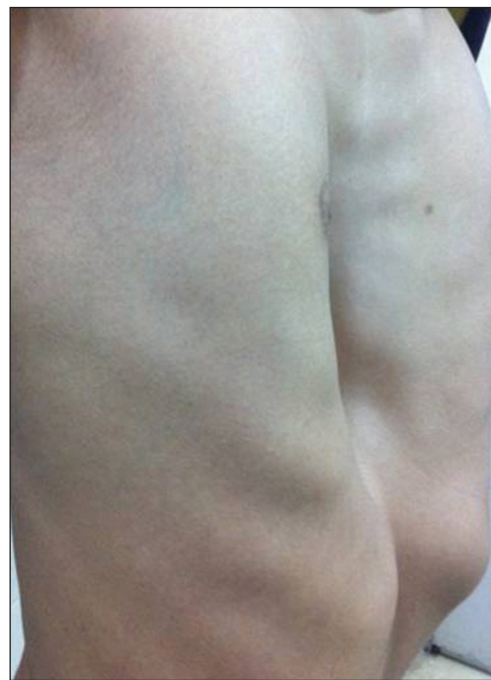

Fig. 1.22 An oblique view of the same patient as in Fig. 1.21.

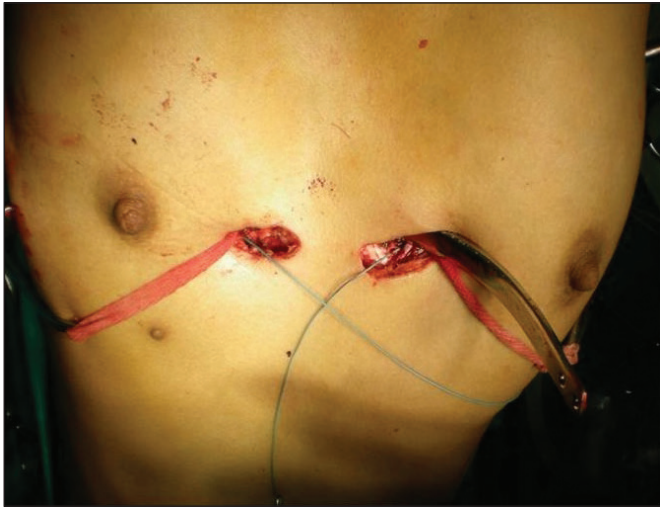


Fig. 1.23 Nuss procedure. An intraoperative photograph shows the pectus bar being placed under the deformed cartilages and the sternum through small transverse incisions.

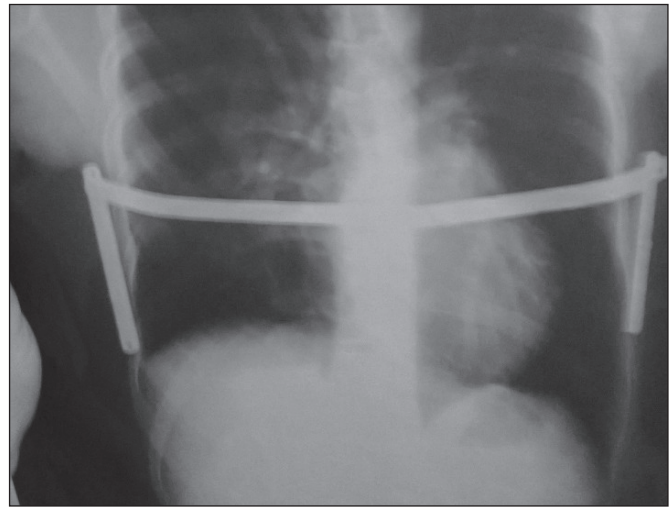


Fig. 1.24 A postoperative chest radiograph of the same patient as in **Fig. 1.23** showing the implant satisfactorily in position with no obvious evidence of intrathoracic injury.

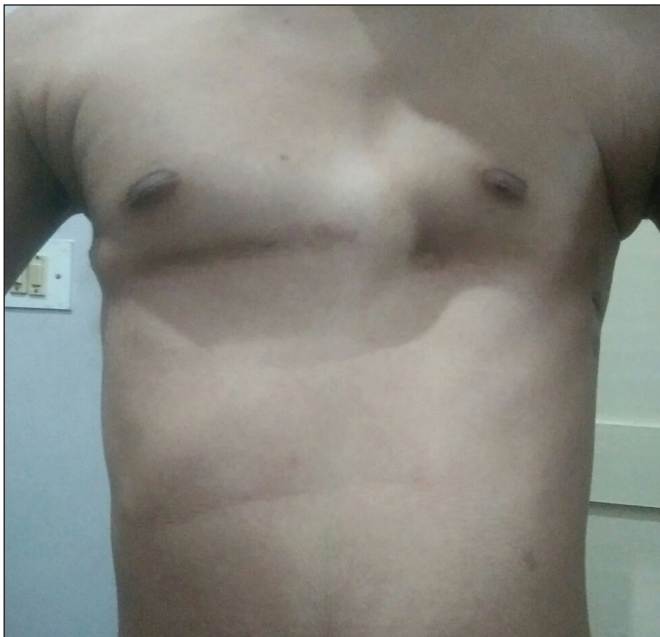

Fig. 1.25 A frontal view of the same patient after removal of the bar 2 years after surgery.

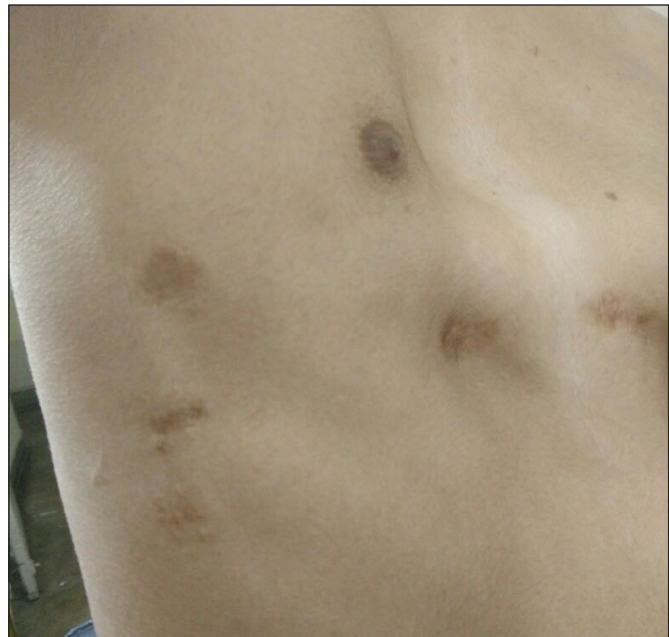

Fig. 1.26 An oblique postoperative view showing the correction of the deformity.

to mitigate that problem. Even though the overall operative time is invariably prolonged in comparison,⁵⁵ it may be of value just for that advantage.

Postoperative Care

While hospitalized and until 2 weeks postoperatively, intensive spirometry is recommended 10 times per hour while awake to minimize respiratory complications. A patient-controlled analgesia pump is used for pain control up to the

second postoperative day, at which time the patients are transitioned to oral pain medication. Hospital stays range from 3 to 6 days.

Outcomes/Comparison

Both types of surgical procedures are reasonably safe and effective. However, Ravitch procedure involves a complex dissection and necessitates a midline scar that may be a problem to tackle in the Indian skin. Therefore, minimally

invasive procedures may be of value for the dark-complexioned population.

Complications

Complications for both surgical techniques are low and of similar frequency. A recent study from the last 21 years including 1,123 primary and 92 redo repairs performed using the Nuss procedure at the Children's Hospital of the King's Daughters, Norfolk, Virginia documented all possible complications.⁵⁶ Of the 790 patients who have had their bar removed, a good or excellent result was obtained in 96%. Despite the varied results of studies designed to evaluate the pulmonary and cardiac pathophysiological effects of pectus excavatum, the majority of patients indicate subjectively improved exercise tolerance after surgery. Recurrences requiring revision operation should be low, approximately 1.4%.

Pectus Carinatum

Introduction

Pectus carinatum is a chest condition with sternal protrusion characterized by depressions along the sides of the chest, resulting in a bowed-out appearance, similar to a pigeon breast.⁴⁰ The name is derived from a Latin word that means chest with a keel. Pectus carinatum occurs approximately one-tenth as often as pectus excavatum. Children with pectus carinatum usually have normal heart and lung development.

Clinical Profile

Pectus carinatum is the second most common congenital chest wall deformity. It is also frequently referred to as pigeon chest, chicken breast, and pyramidal chest. Similar to pectus excavatum, it is more common in boys than in

girls, with a ratio of 4:1.⁵⁷ Most children present as teenagers because the deformity usually is not appreciated until after 11 years of age, and then worsens with puberty. There is some genetic predisposition because 26% of patients have a family history of chest wall deformities.⁴⁰ In addition, there is an abnormality of connective tissue development because 12% of patients also have scoliosis.⁴⁰ There may be an association too with Marfan's syndrome or Poland syndrome. There are three types of deformities: chondromanubrial, chondrogladiolar, and the lateral variety; the second one being the commonest and the lateral one being the most rare⁵⁸ (Figs. 1.27–1.31). Lateral depression of the ribs accentuates the protrusion and can be asymmetric. Mixed deformities may occur that involve components of both protrusion and depression. There is an increased incidence of congenital heart disease in these children. Most children do not have significant symptoms with this anomaly. Tenderness when lying prone is a common complaint, and in severe cases, patients may complain of shortness of breath. Supplements to the physical examination include posteroanterior and lateral chest radiographs, and in certain cases chest imaging with either a CT or MRI may be helpful (Fig. 1.29).

Treatment

Conservative

Orthotic bracing is the first-line therapy recommended for most patients, especially those who are motivated, have a malleable chest wall, and are younger than 18 years. Success rates of 65 to 80% have been reported with orthotic bracing alone, with good long-term results. Success is strongly dependent on the patient's motivation and chest wall flexibility.²³ Martinez-Ferro and colleagues⁵⁹ have reported the use of a dynamic compression system for the correction of the deformity. This device uses a customized aluminum brace with an electronic pressure-measuring device.

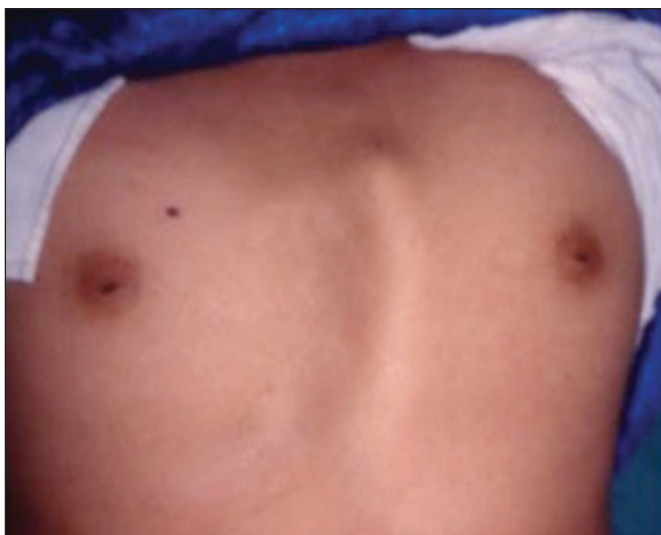

Fig. 1.27 Pectus carinatum of the left side.

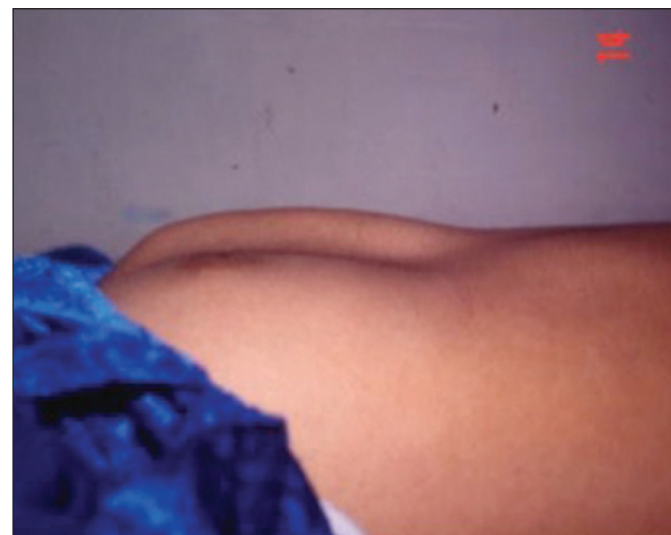

Fig. 1.28 A lateral view of the same deformity.

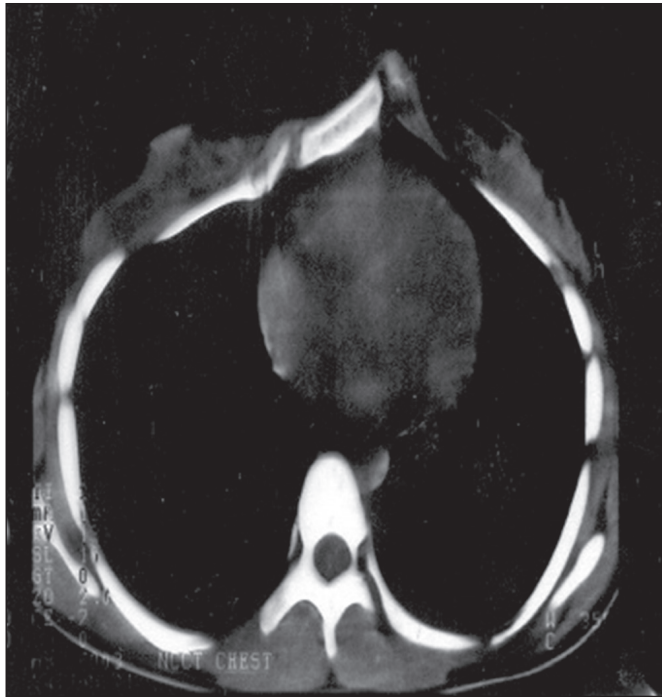

Fig. 1.29 A plain CT scan of the chest confirmed the lateral variety of pectus carinatum.

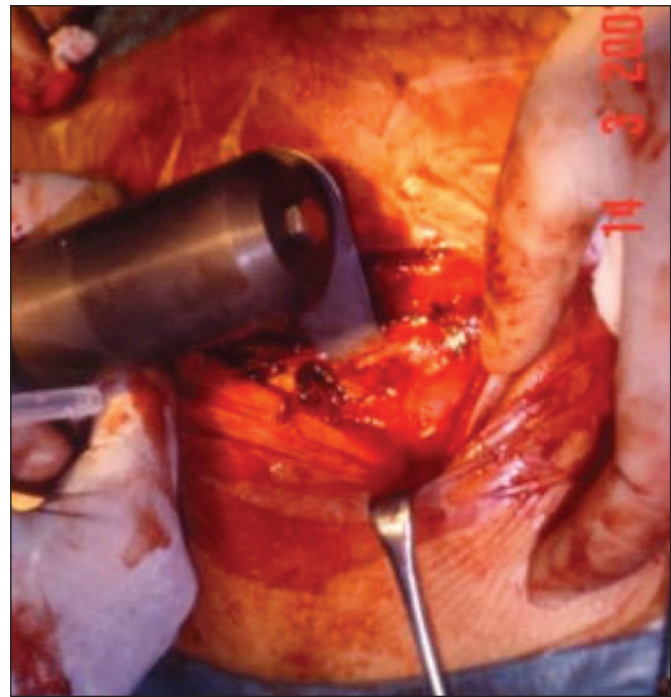

Fig. 1.30 Vertical midline approach—perichondrium incised, deformed cartilages shaved off, and the perichondrial flaps sutured back.

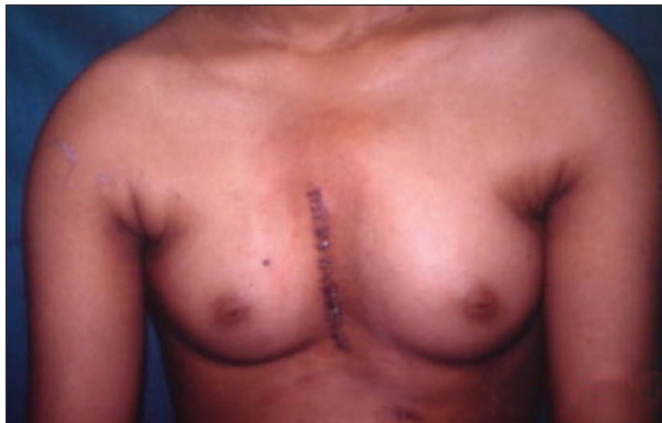

Fig. 1.31 A postoperative frontal view showing satisfactory correction of pectus carinatum in a female patient.

Operative Standard Procedure

Reconstruction involves a modification of the Ravitch technique for pectus excavatum repair (**Fig. 1.32**). The time-honored open approach is most often used and is similar to that used for open repairs of pectus excavatum. This approach was first promoted by Ravitch⁶⁰ in 1952 for the surgical correction of pectus carinatum. A transverse or vertical midline incision is usually made, followed by skin and pectoralis muscle flaps. It is recommended that all deformed cartilages are removed, leaving the perichondrium behind.

The type of deformity of the carinatum defect will dictate subsequent steps in the procedure. For chondrogladiolar defects, double osteotomies are often needed to allow the posterior plate of the sternum to be fractured and return to a more normal position. For mixed defects and asymmetric defects, it is important to resect cartilages on both sides of the sternum to allow it to flatten. A transverse offset wedge-shaped osteotomy is used. Closure of this defect then allows anterior displacement and rotation of the sternum. After cartilage removal, the perichondrial bundles are typically flattened with a series of reefing sutures. Closed suction drains are placed and are usually removed before discharge. Outcomes are usually good to excellent.

Minimally Invasive Procedures

In 2009, Abramson et al⁶¹ from Buenos Aires reported a 5-year experience with a minimally invasive technique for pectus carinatum repair. With this technique, a Nuss bar is tunneled subcutaneously via lateral thoracic incisions and placed anterior to the sternum. Stabilizers are attached to the ribs on both sides with subperiosteally placed wires. The bar is then attached to the stabilizers and secured, once the desired configuration of the chest is obtained, with manual pressure. A modification of thoracoscopic cartilage resection for stiff chests has been reported by Kim and Idowu.⁶² The use of these two modifications are still in evolution but initial reports have been promising. Issues with securing the stabilizers to the ribs and securing the bar to the stabilizer

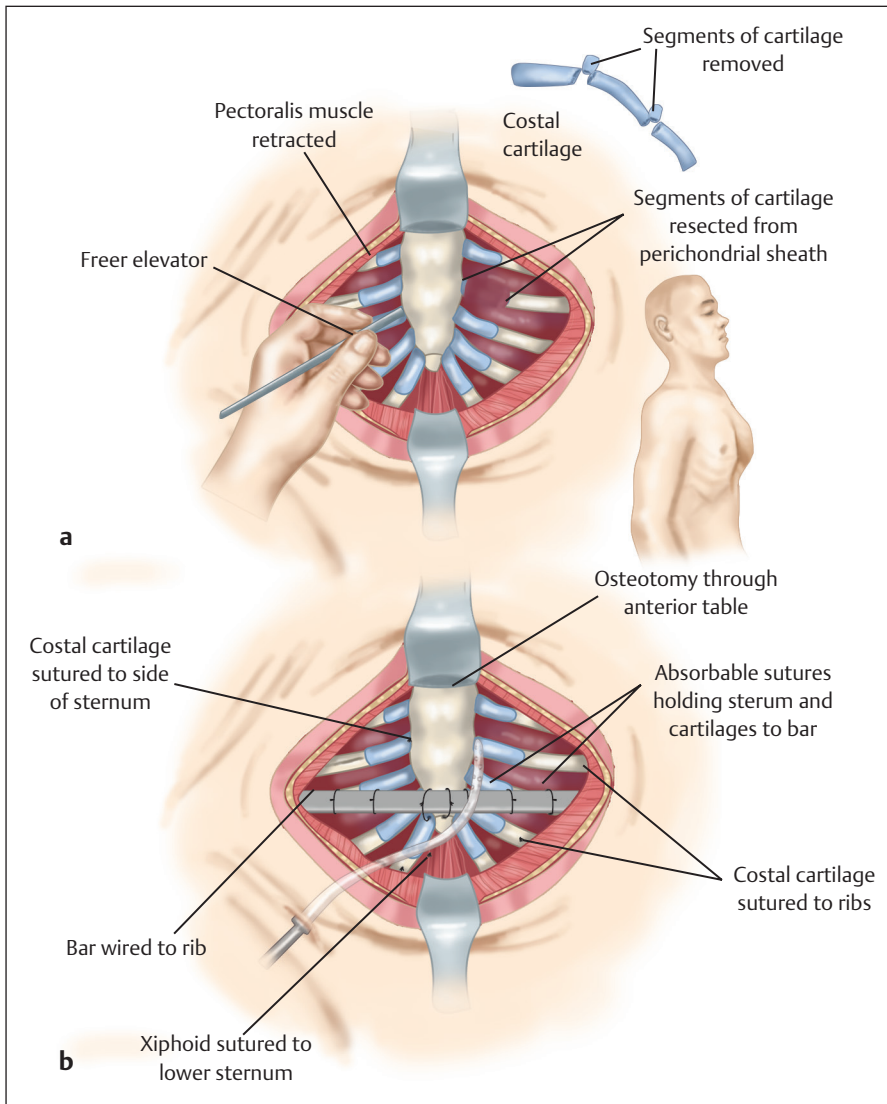


Fig. 1.32 Modified Ravitch approach for pectus carinatum repair. **(a)** Exposure after chevron incision. **(b)** The medial ends of the costal cartilages are sutured to the sternum and the lateral ends are sutured to the ribs.

have been some of the areas of concern that are undergoing further modifications.

Since corrective surgery may require a long vertical midline incision that is prone to scar hypertrophy just like in pectus excavatum correction, especially in the Indian patient, endoscopic assistance may be of value to minimize this complication.

Outcome

Some form of orthotic bracing is the first-line therapy for pectus carinatum. With essentially no morbidity except minor skin irritation, a trial for bracing should be given for at least 12 to 24 months. In compliant patients, who have not finished puberty, success rates approaching 80% have been reported.⁶³ In older patients with stiff chests, bypassing bracing and going straight to surgery is reasonable. Overall success from the surgical techniques is high, with minimal complications. Patients have reported a subjective

improvement in chest discomfort, dyspnea, and stamina after repair, but any objective reports are limited.

Complications

Most complications are minor and consist of wound infections, pneumothorax, pneumonia, wound separation, and minor cosmetic issues. Recurrence is rare and is usually associated with incomplete initial repair and repair at an early age.⁴⁰

Poland Syndrome

Introduction

Poland syndrome is a severe form of chest wall and breast hypoplasia that occurs in 1 in 7,000 to 100,000 live births.⁵⁷ In 1841, Alfred Poland, a 19-year-old medical student at Guy’s Hospital in London, England, published the classic description of the syndrome that bears his name.

Poland's initial description of the deformity that bears his name included absence of the pectoralis major and minor muscles and syndactyly of the ipsilateral hand (**Fig. 1.33**). Baudinne later referred to the set of deformities as Poland syndrome.⁵⁸

Clinical Profile

Congenital unilateral absence of the sternocostal head of the pectoralis major muscle is considered to be pathognomonic for Poland syndrome. The full spectrum of the anomaly—in addition to those initially noted by Poland—includes absence of multiple ribs with chest wall depression, athelia

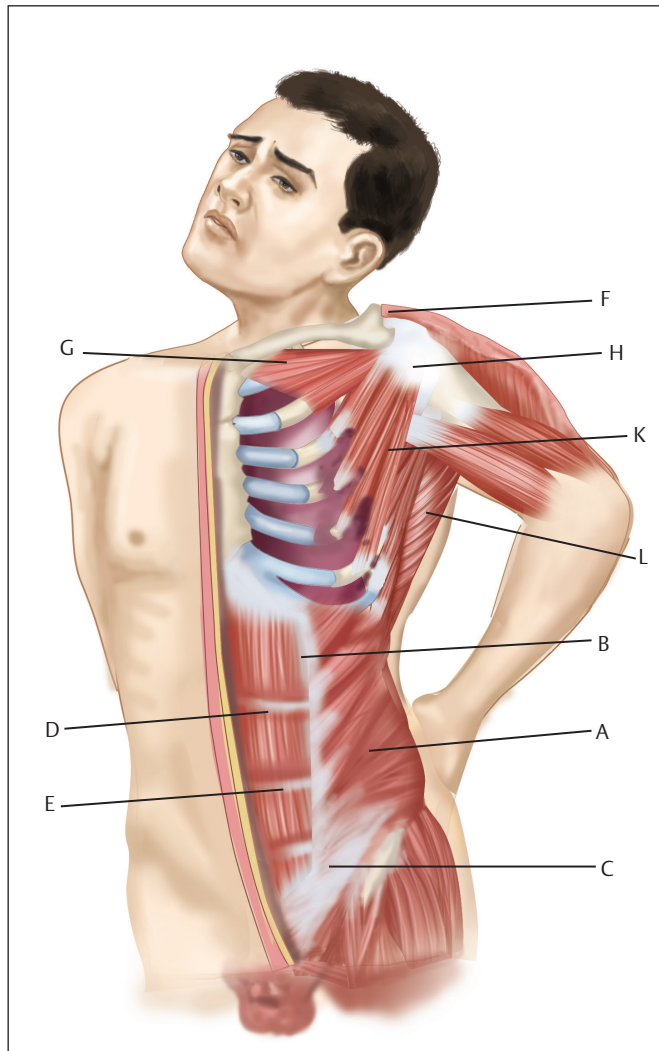


Fig. 1.33 Adapted illustration from Alfred Poland's original article published in *Guy's Hospital Reports* in 1841 shows the severe form of Poland syndrome. A, external abdominal oblique muscle; B, a slip of the same muscle arising from the eighth rib; C, tendon of the external oblique muscle; D, part of the internal oblique muscle, uncovered by the external muscle; E, sheath of the rectus; F, deltoid; G, clavicular portion of the pectoralis major; H, subscapularis; K, teres major; L, latissimus dorsi.

or amastia, absence of axillary hair, potential absence of the latissimus dorsi muscle, limited subcutaneous chest wall fat, and brachysyndactyly (**Fig. 1.34**); the anomaly may be unilateral or, more rarely, bilateral, sporadic, or familial. The breast tissues may be small or absent and the nipple–areola complex can be small, lightly pigmented, and displaced toward the axilla. There is a predilection for the complex in male subjects, and a right-sided prevalence. Although Poland syndrome is usually a sporadic condition, cases of family history with Poland syndrome have been recorded⁵⁹ (**Figs. 1.35–1.37**). The fact that the defect is unilateral has stimulated theories of causal events in utero. Although vascular abnormalities have been proposed, the mechanism remains obscure. The sparing of other musculoskeletal units on the affected side, many of which are quite functional, has been difficult to explain. The chest wall deficiency in Poland syndrome is primarily cosmetic. The most functional limitation is related to the syndactyly. Therefore, providing reassurance to the patients and their families as to their abilities is an important component of the surgeon's mission.

There are two major variations of Poland syndrome: the simple or mild form and the complex or severe form.

Simple Form

This most common form is characterized by absence of the large, fan-shaped sternocostal head of the pectoralis major muscle. This renders the ipsilateral axillary fold deficient. The clavicular head is present as a thin triangular bundle that attaches the humerus to the inferomedial third of the clavicle. The breast and nipple–areola complex are smaller and displaced somewhat toward the axilla. If the lengths of the clavicle, humerus, ulna, and phalanges are measured, they are usually found to be smaller on the affected side.⁶⁴

Complex Form

The complex form, as in Poland's subject, is characterized by absence of the sternocostal head of the pectoralis major muscle, rib and sternal aberrations, muscular displacements, and often a relatively severe brachysyndactyly. The clavicular head may be diminutive, and the entire ipsilateral hemithorax and upper extremity components are notably smaller, even without measurement. An axillary web may be seen (**Fig. 1.37**) and seems to contain muscle tissue because some patients (or an electrocautery during surgery) can cause it to contract. It may therefore represent a forme fruste of the missing pectoralis major muscle. The serratus anterior may be absent, causing a winged scapula. The sternal body (gladiolus) and xiphoid process may be short and bifid, and the sternocostal cartilages on the affected side may be rotated and coalesced into a vertical bar. The insertion of the ipsilateral rectus abdominis muscle may be high. The anterior bodies of ribs two through five are thin and short, and their cartilages are often missing superolaterally. These latter are replaced by a tough pleurofascial membrane that can be seen to move with respirations.⁶⁴

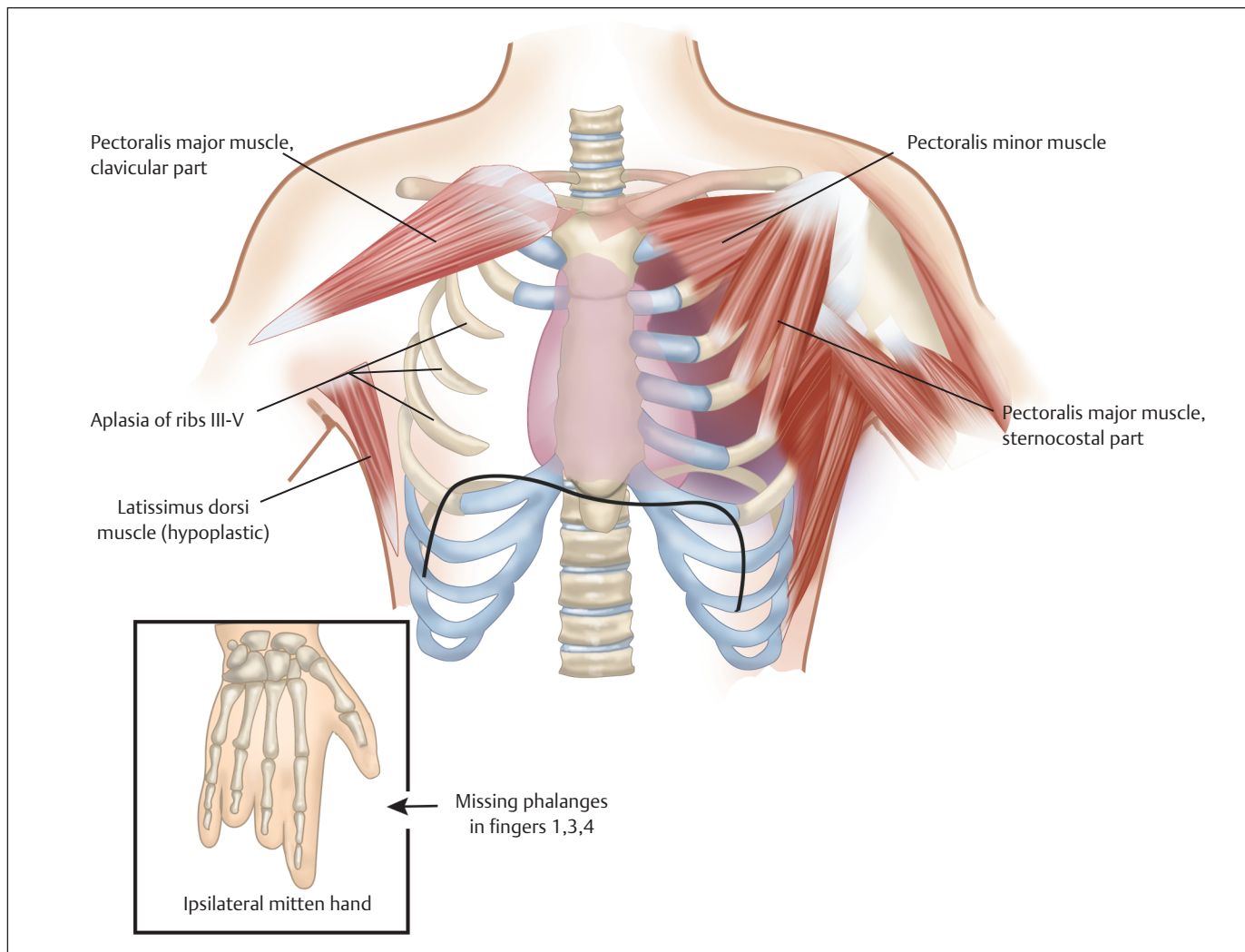


Fig. 1.34 Schematic representation of feature of Poland syndrome.

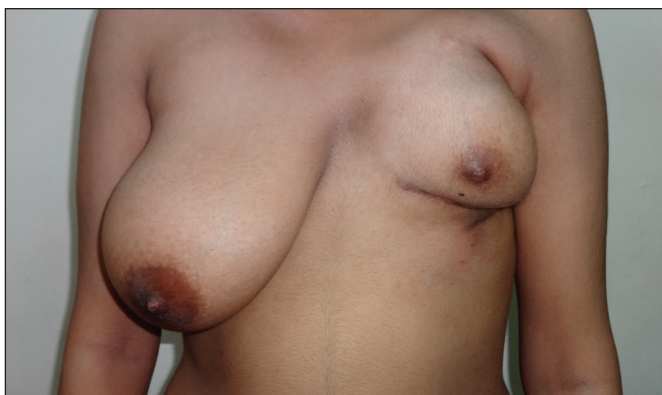

Fig. 1.35 The elder of two sisters with complex forms of Poland syndrome (familial variety) showing the poorly developed left half of the chest wall.

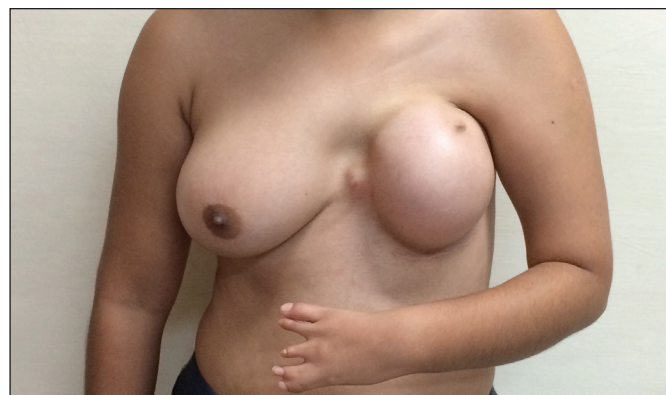

Fig. 1.36 The younger of the two sisters also with a complex form of Poland syndrome. Note the breast aplasia (the mound is made primarily by an expander placed to expand the skin envelope) with rudimentary nipple areola complex that is shifted upward and medially on the left. There is associated symbrachydactyly of the ipsilateral hand. (This image is provided courtesy of Dr S. K. Singh, New Delhi, India.)

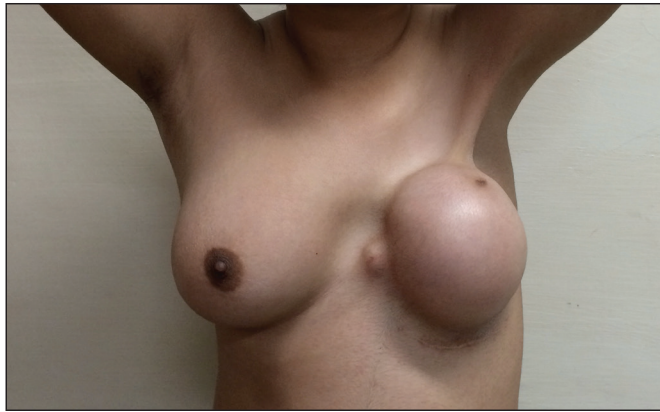

Fig. 1.37 The same patient as in **Fig. 1.36** showing an axillary web on the affected side on abduction of the shoulder.

Treatment

No conservative or nonoperative treatment can ameliorate the deformity. Methods of chest wall repair include pedicle latissimus dorsi muscle transfer if not involved, usually with a mammary implant, a mammary implant alone in the mild cases, pedicle transverse rectus abdominis musculocutaneous (TRAM) flap, sternal/rib reconstruction (**Figs. 1.38 and 1.39**), custom chest wall implant insertion, nipple-areola complex repositioning, contralateral operations (to ameliorate asymmetry), revisions, or a combination of these procedures. Treatment options for the breast and chest wall anomalies include autologous tissue,⁶⁰ either pedicled (latissimus or rectus abdominis) or free musculocutaneous flaps (rectus abdominis), or synthetic materials⁶¹ alone or in combination.

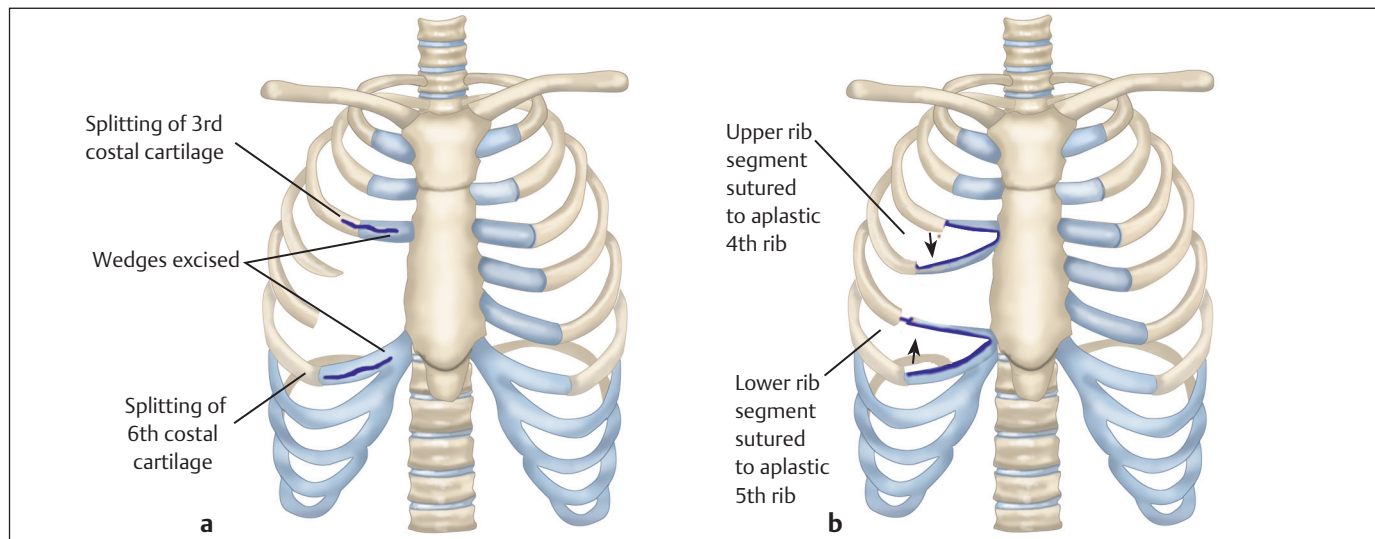


Fig. 1.38 (a, b) Repair of minor Poland syndrome thoracic defects with split rib rotational grafts.

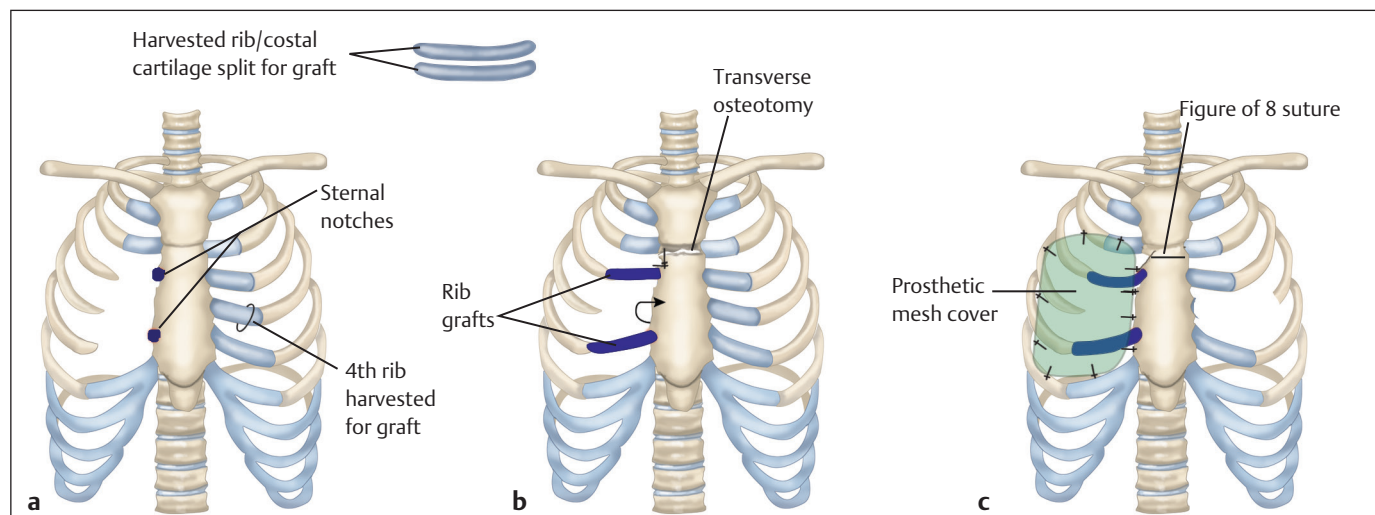


Fig. 1.39 Stabilization of major chest wall defects with split rib grafts and mesh prosthesis. (a) Poland syndrome right side with absent 3rd to 5th costal cartilages. (b) Sternal osteotomy performed (if necessary) to rotate sternum into normal position and split rib grafts inset. (c) Prosthetic mesh is sutured on top of the rib grafts and to the edges of the defect.

Surgical Options for the Simple Form

In female patients, mild cases may be satisfactorily treated with a mammary prosthesis alone (Figs. 1.40 and 1.41). However, this option can accentuate subclavicular hollowing and due to the natural tightness of the parasternal tissues, the implant may easily migrate into this space. This can result in a high-riding, misshapen breast mound that is distressing. Additions to the mammary implant can include a customized chest wall implant, a TRAM flap, and/or a latissimus muscle transfer, all of which can provide shape and volume to the deficient upper chest wall. The custom chest wall prosthesis is a good alternative because it is relatively simple to fabricate and insert, and may offer the promise of a natural feel⁶² (Fig. 1.42). In contrast, a latissimus muscle transfer in combination with a sublatissimus mammary prosthesis satisfactorily fills the subclavicular hollow and provides an even more natural feel and appearance (Fig. 1.43). This latter combination is also remarkably free of problems. Some authors have advocated the use of endoscopy to assist in the harvest and placement of the latissimus dorsi flap⁶⁵; a relatively small incision may suffice for harvest and placement of the flap, obviating the need for endoscopic instrumentation. Once harvested, the latissimus flap must be inset carefully along the infraclavicular margin to prevent recurrence of the infraclavicular hollow. Finally, to optimize symmetry, female patients often request and receive treatment of the opposite (normal) breast with a mastopexy or a reduction mammoplasty.

In male patients, the objective is to replace the missing pectoralis major, and the surgical preference may be the latissimus muscle transfer.

In both sexes, the latissimus transfers are performed through an axillary incision that parallels the upper anterior border of the latissimus muscle and extends into the axillary crease. Because the latissimus and pectoralis major muscles both originate from a median structure, insert on the humerus, and are adductors and medial rotators of the humerus, the latissimus transfer requires no reeducation

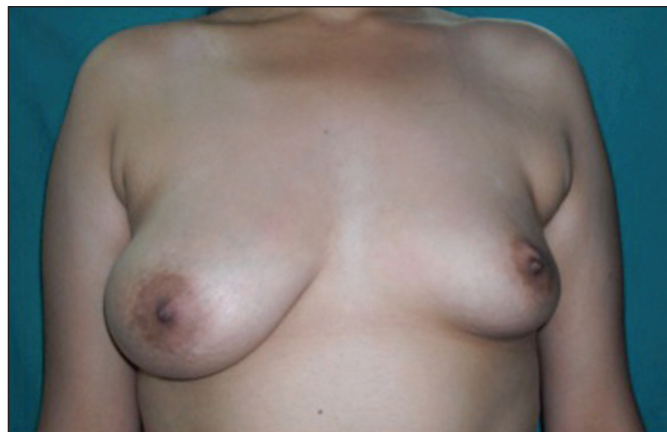

Fig. 1.40 A simple form of Poland syndrome manifesting as hypoplasia of the left breast with asymmetry.

when the patient activates it. In each case, the entire muscle is harvested and, although most patients find this not to be objectionable, they must be informed that this lessens the volume of their posterior axillary fold on that side. A tissue expander is appropriate in some cases, especially in the complex variety to expand the overlying skin envelope as a prelude to final reconstruction (Figs. 1.35–1.37). Microsurgical free flaps or endoscopically assisted repairs may also be appropriate, depending on the patient and the experience of the surgeon.⁶²

Surgical Options for the Complex Form

In this form, as noted earlier, the ipsilateral rectus abdominis muscle can be malpositioned, attached to a short, possibly bifid, sternum, and connected to a thick, ipsilateral bar of protruding cartilage. The protruding bar can usually be repositioned to effectively flatten the chest wall and a latissimus muscle transfer can be performed. In female patients, a mammary prosthesis can be placed subjacent to the transferred muscle and, in both sexes, a final restoration or repositioning of the nipple–areola complex can be performed later under local anesthesia.

Role of Tissue Expansion Followed by Breast Implant

If a young female patient exhibits anxiety associated with the breast deformity, early treatment with a temporary expander may be instituted, planning for definitive reconstruction once the breast development has been completed. A subcutaneous tissue expander can be placed in the affected side since the pectoralis muscle is absent. This expander can be inflated at weekly or twice-weekly intervals after wound healing occurs to match the development of the unaffected breast. This expanded breast does not exactly match the uninvolved side but may help the patient look more symmetrical. Placement of the expander during breast development allows for expansion of the skin to accommodate the eventual permanent implant and latissimus muscle. Moreover, this expansion of the breast skin may enlarge and

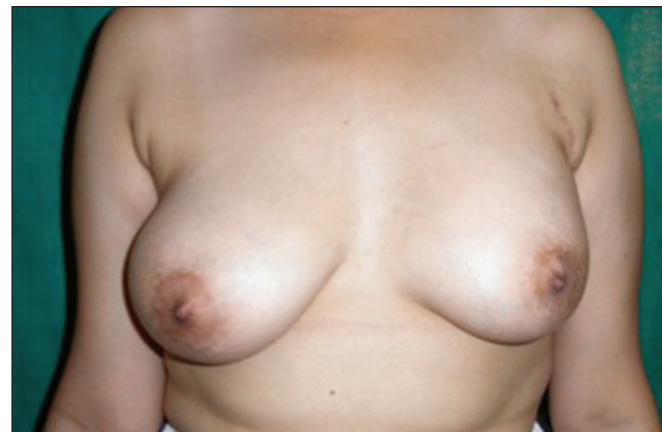

Fig. 1.41 Eighteen months postoperatively after reconstruction with silicone implant (230 g).

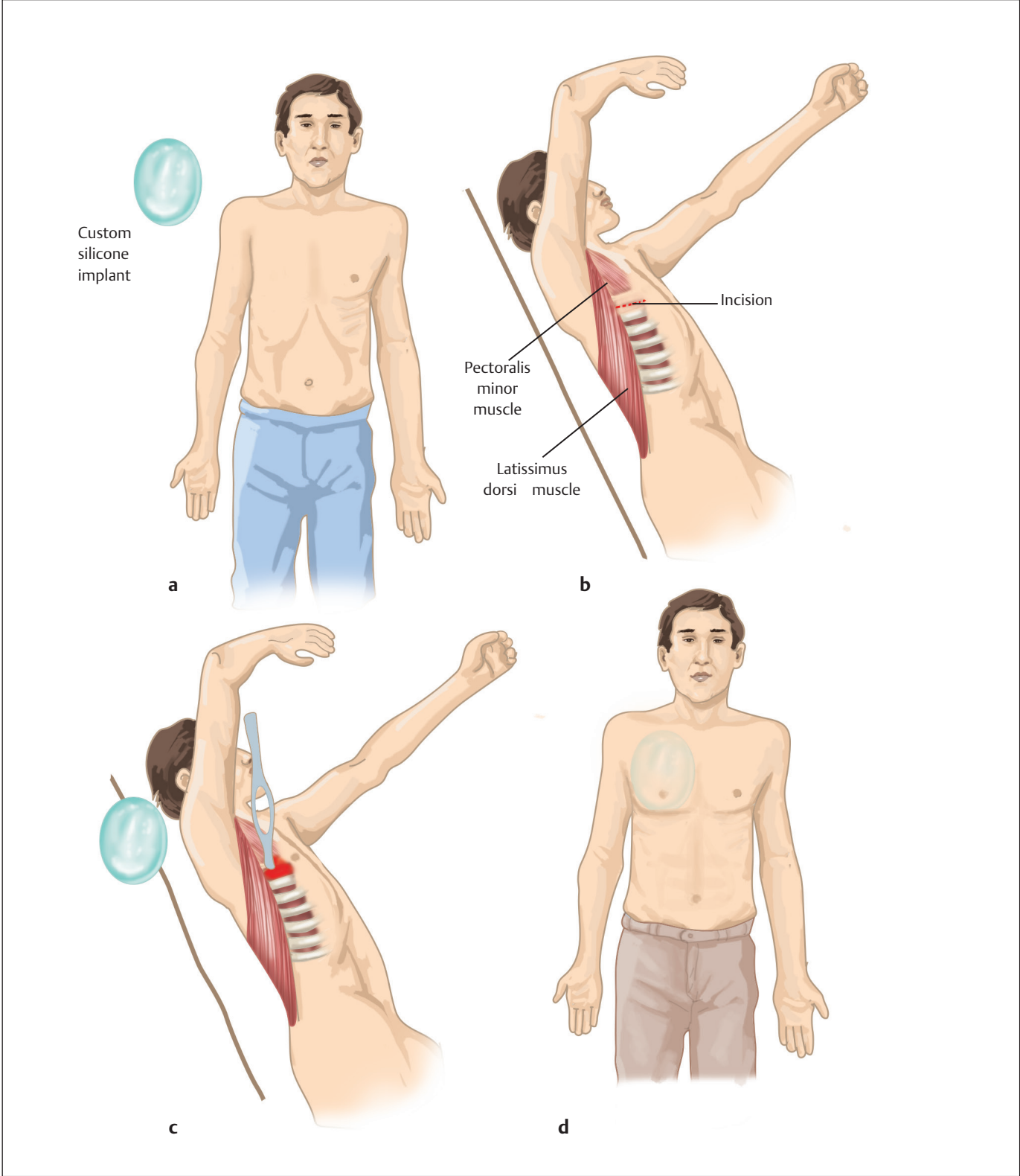


Fig. 1.42 Technique for silicone implant for pectoralis major contour defect correction in Poland syndrome. **(a)** Absent right pectoralis major. Customized implant prepared from moulage of defect. **(b)** Patient in left lateral decubitus position. **(c)** After pocket dissection, the implant is inserted into position over the pectoralis minor and exposed chest wall. **(d)** No implant fixation is required.

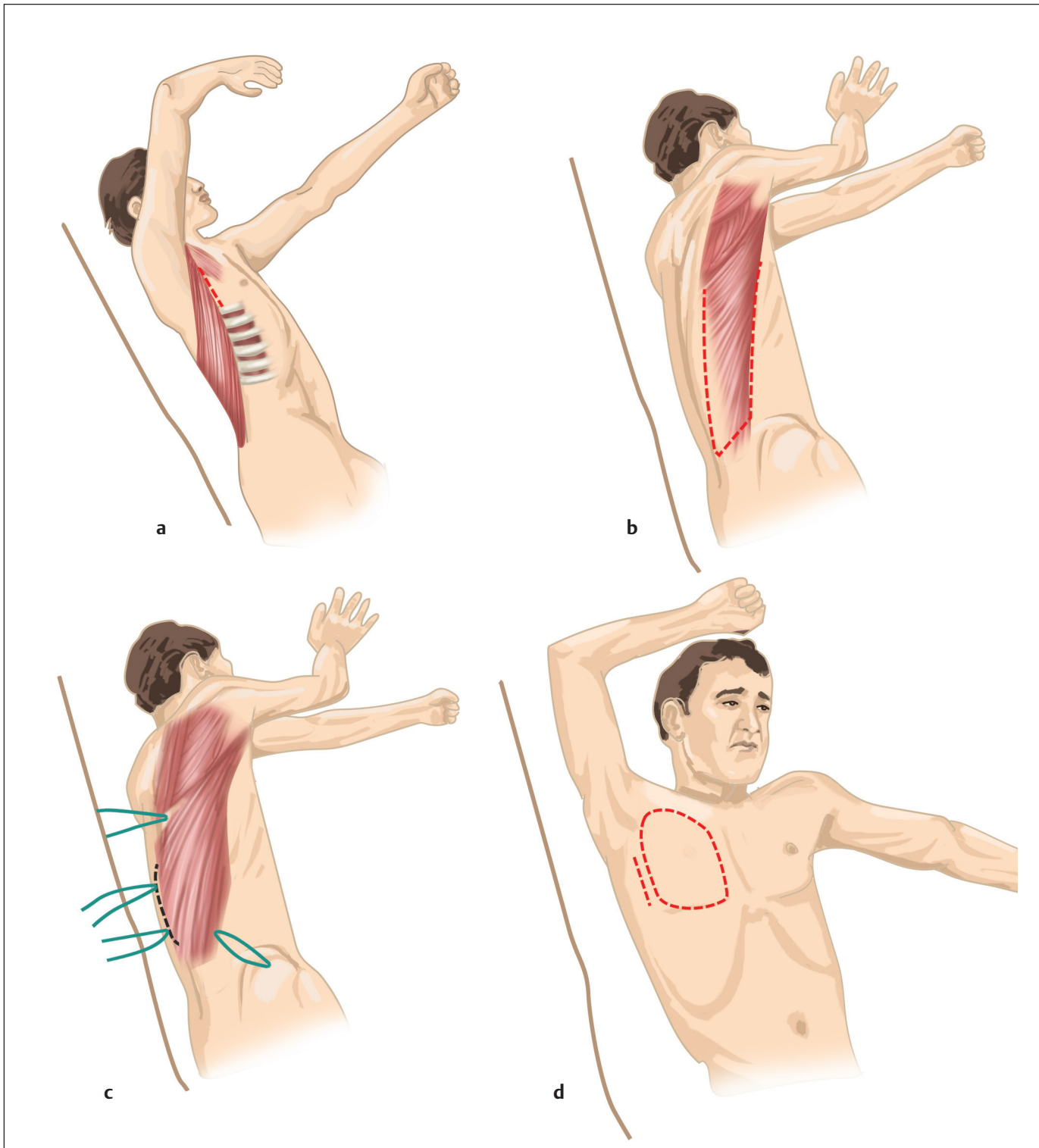


Fig. 1.43 Operative technique, latissimus dorsi functional muscle transposition. **(a)** The lateral decubitus position is used for muscle dissection and inset. **(b)** Latissimus dorsi muscle dissection on the posterior side. **(c)** Muscle dissection proceeds into the axilla with division of congenital adhesions to teres major muscle and identification of thoracodorsal artery, vein, and nerve. **(d)** Supine position for anterior dissection of space for muscle transposition.

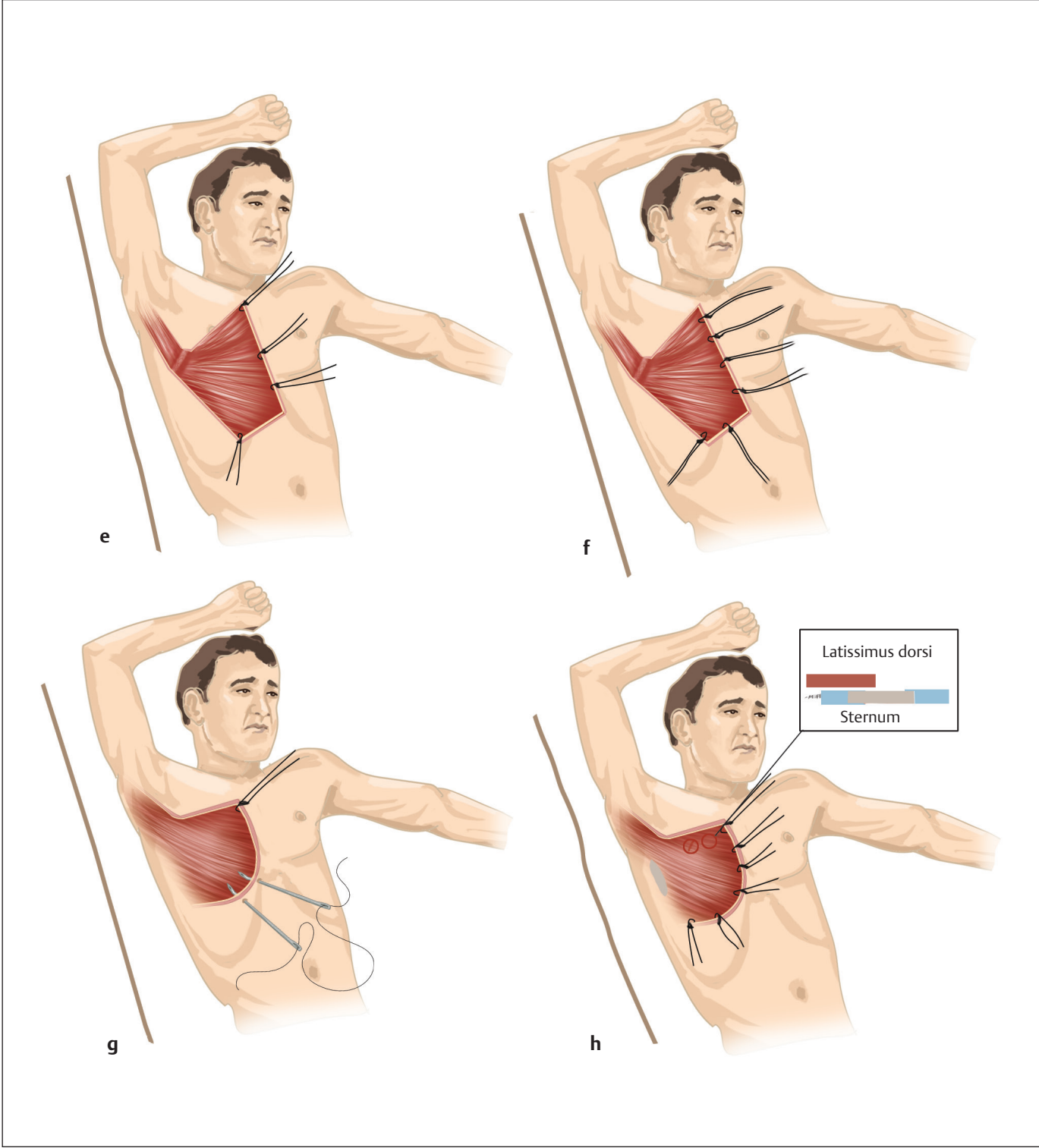


Fig. 1.43 (Continued) **(e)** New latissimus muscle origin is established at inframammary line and along the sternal edge. **(f)** Nonabsorbable sutures passed through muscle origin in horizontal mattress fashion at intervals of 2 to 3 cm. **(g)** A Keith needle with both suture ends threaded through the needle eye is passed through the skin slightly medial to the sternal edge and inferior to the inframammary line. **(h)** Before these sutures passing through the skin are tied, absorbable sutures are placed on the deep surface of muscle origin to the sternal edge and the sixth rib of periosteum.

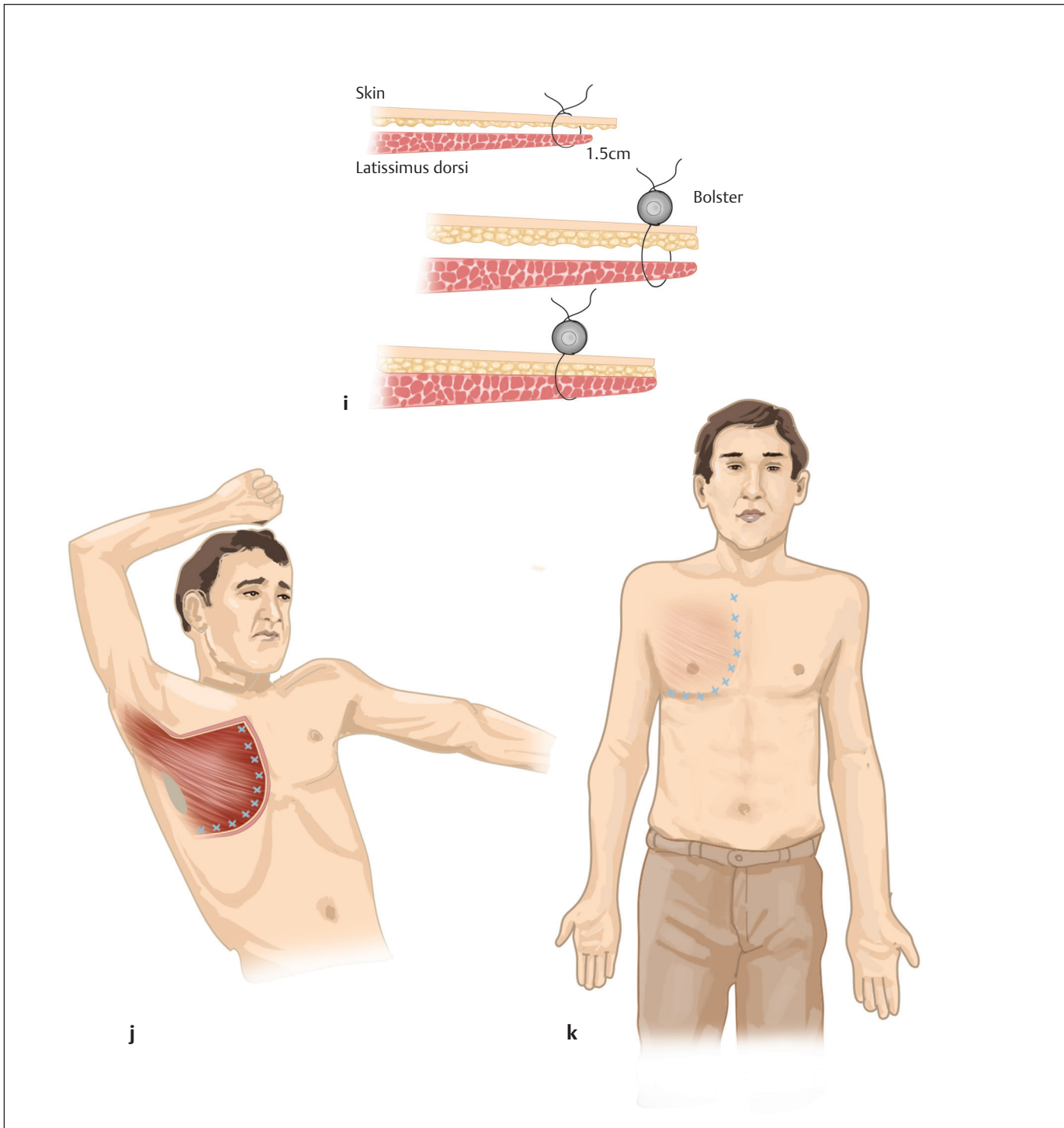


Fig. 1.43 (Continued) **(i)** Close-up of technique to reestablish latissimus dorsi muscle origin. Nonabsorbable sutures are passed through muscle origin and tied over bolster dressing. **(j)** Latissimus dorsi muscle origin is established with nonabsorbable bolster sutures through the skin and deep absorbable sutures to the sternum and along inframammary line at the sixth rib. **(k)** Bolster sutures are removed in 10 to 14 days. Muscle contraction is avoided for 6 weeks.

correct the hypoplastic and eccentric nipple–areola complex often present in these patients.⁶³ Tissue expansion can be performed with a pure temporary tissue expander that is eventually replaced with a permanent implant or with a permanent implant expander.

If the latissimus dorsi is absent, other options for reconstruction may include free latissimus dorsi muscle from the opposite side, the TRAM flap, Rubens' flap, gluteus maximus flap, thigh flap, or free perforator TRAM, deep inferior epigastric perforator (DIEP), or gluteal artery flaps. As thoracic vascular anomalies also can be encountered in patients with Poland syndrome, assessment of recipient vessels with color Doppler or CT angiogram may be required.⁶⁶ However, invariably, the best results with free tissue transfer are with contralateral latissimus flap or free DIEP flap as the others usually need venous grafts for microanastomoses.

Fat transfer is a recent advance, indeed a shot in the arm, in the management of the deformities associated with Poland syndrome. It also could be theorized that the injected fat triggers stem cell differentiation within the affected area. This technique can be used effectively to fill out the hollowing and also help in minimizing the asymmetry by lipofilling of the opposite breast too. The obvious advantages of the technique are myriad. The few drawbacks are as follow:

- Multiple sessions may be required for the final result as there may be fat resorption.
- Large-volume transfers are usually not possible in one sitting.
- The cosmetic results of breast fat grafting procedure may be inconsistent.

Microcalcification, which may cause false positives in breast cancer screening, can appear commonly. A preoperative mammogram should be done.

Timing of Chest Wall Repair

In some cases, there may be reasons to proceed with repair at an early age, especially with the severe form, it is generally preferred to delay most of these procedures until late adolescence or adulthood. The arguments for waiting include the risk of growth inhibition if operative trauma is administered too early, the right of the patient to participate in competent decisions, and the unfortunate necessity for revision procedures.

An entity separate from Poland's anomaly, referred to as anterior thoracic hypoplasia, has been reported.⁶⁷ These patients have a unilateral sunken chest wall, hypoplasia of the breast, and a superiorly displaced nipple–areola complex; importantly, these individuals have a normal sternal position and a normal pectoralis muscle. Augmentation mammoplasty alone has been successfully used to treat these individuals.

Sternal Clefts

Isolated cleft of the sternum is a rare congenital malformation resulting from a fusion failure of the sternum. Congenital sternal occurs in fewer than 1 in 100,000 live births.⁶⁸ Acastello and colleagues stated that it represented 0.15% of all patients with a chest wall malformation in their patient population of 5,182 observed over a 25-year period.⁶⁶

Etiology of cleft sternum remains obscure. It is thought to arise from a failure of development or ventral fusion of the sternal bars at about the eighth week of gestation (**Fig. 1.18**). Sternal cleft can be classified into three major groups: cleft sternum without associated anomalies, thoracic or true ectopia cordis with varying degrees of cleft sternum with the heart outside the chest wall, and thoracoabdominal ectopia cordis, which is referred to as Cantrell's pentalogy. Typically, with a partial sternal cleft, there is skin coverage of the midline defect with an intact pericardium and a normal diaphragm.⁶⁹

Surgical correction is indicated to protect the heart and great vessels from injury, to improve respiratory dynamics, and to restore a good aesthetic appearance. Early correction allows for an easy direct closure due to flexibility of the chest and results in a lower risk of cardiac compression.^{63,66} The goals of therapy should be to safely provide adequate protection of the thoracic viscera, maintain the growth potential of the chest wall, avoid the use of prosthetic material when possible, and attain a satisfactory cosmetic result. When diagnosed in the neonatal period, a sternal cleft should be closed primarily. During this time, the chest wall is maximally flexible. Over time, the thoracic organs accommodate to the size of the thoracic cavity and defect, making primary closure more difficult in the older child. For them, Ravitch procedure or use of autologous tissue or prosthetic material can be used to good effect.

References

1. Pfannschmidt J, Geisbüsch P, Muley T, Dienemann H, Hoffmann H. Surgical treatment of primary soft tissue sarcomas involving the chest: experiences in 25 patients. *Thorac Cardiovasc Surg* 2006;54(3):182–187
2. Tansini I. Sopra il mio nuovo processo di amputazione della mammilla. *Gazz Med Ital* 1906;57:141
3. Watson WL, James AG. Fascia lata grafts for chest wall defects. *J Thorac Surg* 1947;16(4):399–406
4. Campbell DA. Reconstruction of the anterior thoracic wall. *J Thorac Surg* 1950;19(3):456–461
5. Julian OC, Lopez-Belio M, Dye WS, Javid H, Grove WJ. The median sternal incision in intracardiac surgery with extracorporeal circulation; a general evaluation of its use in heart surgery. *Surgery* 1957;42(4):753–761
6. Landes G, Harris PG, Sampalis JS, et al. Outcomes in the management of sternal dehiscence by plastic surgery: a ten-year review in one university center. *Ann Plast Surg* 2007;59(6):659–666

34 Trunk and Genitalia

7. Loop FD, Lytle BW, Cosgrove DM, et al. J. Maxwell Chamberlain memorial paper. Sternal wound complications after isolated coronary artery bypass grafting: early and late mortality, morbidity, and cost of care. *Ann Thorac Surg* 1990;49(2):179–186, discussion 186–187
8. Shumacker HB Jr, Mandelbaum I. Continuous antibiotic irrigation in the treatment of infection. *Arch Surg* 1963;86:384–387
9. Lee AB Jr, Schimert G, Shaktin S, Seigel JH. Total excision of the sternum and thoracic pedicle transposition of the greater omentum; useful strategies in managing severe mediastinal infection following open heart surgery. *Surgery* 1976;80(4):433–436
10. Jurkiewicz MJ, Bostwick J III, Hester TR, Bishop JB, Craver J. Infected median sternotomy wound. Successful treatment by muscle flaps. *Ann Surg* 1980;191(6):738–744
11. Cicilioni OJ Jr, Stieg FH III, Papanicolaou G. Sternal wound reconstruction with transverse plate fixation. *Plast Reconstr Surg* 2005;115(5):1297–1303
12. Sahasrabudhe P, Jagtap R, Waykole P, Panse N, Bhargava P, Patwardhan S. Our experience with pectoralis major flap for management of sternal dehiscence: a review of 25 cases. *Indian J Plast Surg* 2011;44(3):405–413
13. Agarwal JP, Ogilvie M, Wu LC, et al. Vacuum-assisted closure for sternal wounds: a first-line therapeutic management approach. *Plast Reconstr Surg* 2005;116(4):1035–1040, discussion 1041–1043
14. Golosow LM, Wagner JD, Feeley M, et al. Risk factors for predicting surgical salvage of sternal wound-healing complications. *Ann Plast Surg* 1999;43(1):30–35
15. Shah AA, D'Amico TA. Primary chest wall tumors. *J Am Coll Surg* 2010;210(3):360–366
16. Incarbone M, Pastorino U. Surgical treatment of chest wall tumors. *World J Surg* 2001;25(2):218–230
17. Sarkar P, Chandak T, Shah R, Talwar A. Diagnosis and management bronchopleural fistula. *Indian J Chest Dis Allied Sci* 2010;52(2):97–104
18. Cooper WA, Miller JI Jr. Management of bronchopleural fistula after lobectomy. *Semin Thorac Cardiovasc Surg* 2001;13(1):8–12
19. Eloesser L. An operation for tuberculous empyema. *Surg Gynecol Obstet* 1935;60:1096–1097
20. Clagett OT, Geraci JE. A procedure for the management of post-pneumonectomy empyema. *J Thorac Cardiovasc Surg* 1963;45:141–145
21. Raz DJ, Clancy SL, Erhunmwunsee LJ. Surgical management of the radiated chest wall and its complications. *Thorac Surg Clin* 2017;27(2):171–179
22. Vijaykumar DK, Vijayaraghavan S. Reconstruction of chest, abdominal walls and perineum. *Indian J Plast Surg* 2007;40(12):S90–S91
23. Althubaiti G, Butler CE. Abdominal wall and chest wall reconstruction. *Plast Reconstr Surg* 2014;133(5):688e–701e
24. Lardinois D, Müller M, Furrer M, et al. Functional assessment of chest wall integrity after methylmethacrylate reconstruction. *Ann Thorac Surg* 2000;69(3):919–923
25. Aghajanzadeh M, Alavi A, Aghajanzadeh G, Ebrahimi H, Jahromi SK, Massahnia S. Reconstruction of chest wall using a two-layer prolene mesh and bone cement sandwich. *Indian J Surg* 2015;77(1):39–43
26. Agrawal K, Subbarao KS, Nachiappan M, Arumugam A. An innovative method of reconstruction of large skeletal chest wall defects. *Plast Reconstr Surg* 1998;102(3):839–842
27. Sanna S, Brandolini J, Pardolesi A, et al. Materials and techniques in chest wall reconstruction: a review. *J Vis Surg* 2017;3:95
28. Sandler G, Hayes-Jordan A. Chest wall reconstruction after tumor resection. *Semin Pediatr Surg* 2018;27(3):200–206
29. Zhong D, Wang L, Li X, et al. Advances in research on bony wall reconstruction *Zhongguo Fei Ai Za Zhi* 2018; 21(4): 273–276
30. Khalil HH, Malahias MN, Balasubramanian B, et al. Multidisciplinary oncoplastic approach reduces infection in chest wall resection and reconstruction for malignant chest wall tumors. *Plast Reconstr Surg Glob Open* 2016;4(7):e809
31. Khalil HH, Kalkat M, Malahias MN, et al. Chest wall reconstruction with porcine acellular dermal matrix (strattice) and autologous tissue transfer for high risk patients with chest wall tumors. *Plast Reconstr Surg Glob Open* 2018;6(5):e1703
32. Merritt RE. Chest wall reconstruction without prosthetic material. *Thorac Surg Clin* 2017;27(2):165–169
33. Aubá C, Cabello Á, García-Tutor E. Perforator flaps covering alloplastic materials in full-thickness chest wall defects reconstruction. A safe option? *Plast Reconstr Surg Glob Open* 2017;e1289
34. Jones G, Jurkiewicz MJ, Bostwick J, et al. Management of the infected median sternotomy wound with muscle flaps. The Emory 20-year experience. *Ann Surg* 1997;225(6):766–776, discussion 776–778
35. Pairolero PC, Arnold PG. Chest wall tumors. Experience with 100 consecutive patients. *J Thorac Cardiovasc Surg* 1985;90(3):367–372
36. Mathes SJ, Seyfer AE. Congenital anomalies of the chest wall. *Plastic Surgery*. 2nd ed. Philadelphia, PA: WB Saunders; 2006
37. Obermeyer RJ, Goretsky MJ. Chest wall deformities in pediatric surgery. *Surg Clin North Am* 2012;92(3):669–684, ix
38. Moore KL, Persaud TVN. *Before We Are Born: Essentials of Embryology and Birth Defects*. 5th ed. Philadelphia, PA: WB Saunders; 1998
39. Morshuis WJ, Mulder H, Wapperom G, et al. Pectus excavatum. A clinical study with long-term postoperative follow-up. *Eur J Cardiothorac Surg* 1992;6(6):318–328, discussion 328–329
40. Shamberger RC, Welch KJ. Surgical correction of pectus carinatum. *J Pediatr Surg* 1987;22(1):48–53
41. Malek MH, Fonkalsrud EW, Cooper CB. Ventilatory and cardiovascular responses to exercise in patients with pectus excavatum. *Chest* 2003;124(3):870–882
42. Nakaoka T, Uemura S, Yoshida T, Tanimoto T, Miyake H. Overgrowth of costal cartilage is not the etiology of pectus excavatum. *J Pediatr Surg* 2010;45(10):2015–2018
43. Sweet RH. Pectus excavatum. *Ann Surg* 1944;119(6):922–934
44. Kotzot D, Schwabegger AH. Etiology of chest wall deformities—a genetic review for the treating physician. *J Pediatr Surg* 2009;44(10):2004–2011
45. Garcia VF, Seyfer AE, Graeber GM. Reconstruction of congenital chest-wall deformities. *Surg Clin North Am* 1989;69(5):1103–1118
46. Croitoru DP, Kelly RE Jr, Goretsky MJ, Lawson ML, Swoveland B, Nuss D. Experience and modification update for the minimally invasive Nuss technique for pectus excavatum repair in 303 patients. *J Pediatr Surg* 2002;37(3):437–445
47. Lange F. Thoraxdeformitäten. In: Pfaundler M, Schlossmann A, eds. *Handbuch der Kinderheilkunde, vol V. Chirurgie und orthopädie im kindersalter, vol. 5*. Leipzig (Germany): FCW Vogel; 1910:157
48. Schier F, Bahr M, Klobe E. The vacuum chest wall lifter: an innovative, nonsurgical addition to the management of pectus excavatum. *J Pediatr Surg* 2005;40(3):496–500

49. Haecker FM. The vacuum bell for conservative treatment of pectus excavatum: the Basle experience. *Pediatr Surg Int* 2011;27(6):623–627
50. Ravitch MM. The operative treatment of pectus excavatum. *Ann Surg* 1949;129(4):429–444
51. Shamberger RC, Welch KJ. Surgical repair of pectus excavatum. *J Pediatr Surg* 1988;23(7):615–622
52. Haller JA Jr, Scherer LR, Turner CS, Colombani PM. Evolving management of pectus excavatum based on a single institutional experience of 664 patients. *Ann Surg* 1989;209(5):578–582, discussion 582–583
53. Fonkalsrud EW, Dunn JC, Atkinson JB. Repair of pectus excavatum deformities: 30 years of experience with 375 patients. *Ann Surg* 2000;231(3):443–448
54. Nuss D, Kelly RE Jr, Croitoru DP, Katz ME. A 10-year review of a minimally invasive technique for the correction of pectus excavatum. *J Pediatr Surg* 1998;33(4):545–552
55. Felts E, Jouve JL, Blondel B, Launay F, Lacroix F, Bollini G. Child pectus excavatum: correction by minimally invasive surgery. *Orthop Traumatol Surg Res* 2009;95(3):190–195
56. Kelly RE, Goretsky MJ, Obermeyer R, et al. Twenty-one years of experience with minimally invasive repair of pectus excavatum by the Nuss procedure in 1215 patients. *Ann Surg* 2010;252(6):1072–1081
57. Fonkalsrud EW, Anselmo DM. Less extensive techniques for repair of pectus carinatum: the undertreated chest deformity. *J Am Coll Surg* 2004;198(6):898–905
58. Dogra BB, Singh M, Langer V. Pectus carinatum. *Indian J Plast Surg* 2005;38:157–159
59. Martinez-Ferro M, Fraire C, Bernard S. Dynamic compression system for the correction of pectus carinatum. *Semin Pediatr Surg* 2008;17(3):194–200
60. Ravitch MM. Unusual sternal deformity with cardiac symptoms operative correction. *J Thorac Surg* 1952;23(2):138–144
61. Abramson H, D'Agostino J, Wuscovi S. A 5-year experience with a minimally invasive technique for pectus carinatum repair. *J Pediatr Surg* 2009;44(1):118–123, discussion 123–124
62. Kim S, Idowu O. Minimally invasive thoracoscopic repair of unilateral pectus carinatum. *J Pediatr Surg* 2009;44(2):471–474
63. Egan JC, DuBois JJ, Morphy M, Samples TL, Lindell B. Compressive orthotics in the treatment of asymmetric pectus carinatum: a preliminary report with an objective radiographic marker. *J Pediatr Surg* 2000;35(8):1183–1186
64. Buckwalter VJA, Shah AS. Presentation and treatment of Poland anomaly. *Hand (N Y)* 2016;11(4):389–395
65. Yang CE, Roh TS, Yun IS, Kim YS, Lew DH. Immediate partial breast reconstruction with endoscopic latissimus dorsi muscle flap harvest. *Arch Plast Surg* 2014;41(5):513–519
66. Acastello E, Majluf R, Garrido P, Barbosa LM, Peredo A. Sternal cleft: a surgical opportunity. *J Pediatr Surg* 2003;38(2):178–183
67. Spear SL, Pelletiere CV, Lee ES, Grotting JC. Anterior thoracic hypoplasia: a separate entity from Poland syndrome. *Plast Reconstr Surg* 2004;113(1):69–77, discussion 78–79
68. Jabbad H, Shehata R, Al-Ebrahim K. Successful surgical repair of complete sternal cleft in an adult. *Asian Cardiovasc Thorac Ann* 2010;18(4):376–378
69. Knox L, Tuggle D, Knott-Craig CJ. Repair of congenital sternal clefts in adolescence and infancy. *J Pediatr Surg* 1994;29(12):1513–1516